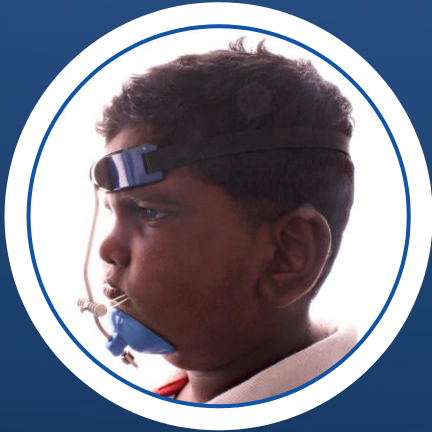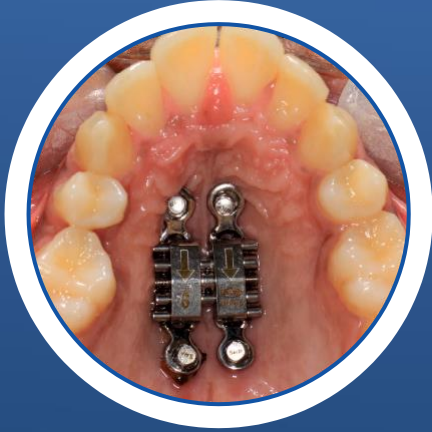

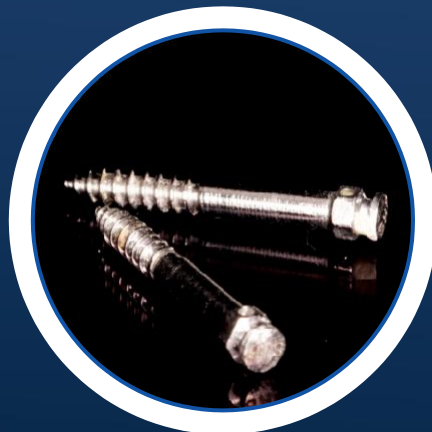
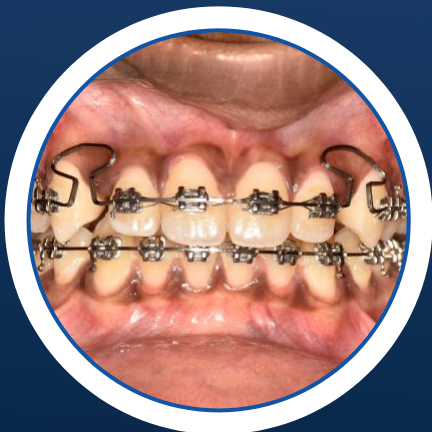Volume 13 Issue-1
January - March 2022

ISSN : 2349 - 5243
E-ISSN : 2542 - 5579



International Journal of
**Orthodontic
Rehabilitation**



REVIEW ARTICLE

FACTORS TO BE CONSIDERED IN ORTHODONTIC INTERDISCIPLINARY APPROACH – A REVIEW

Hamad Alqahtani

Orthodontic Department,

Faculty of Dentistry, King Abdulaziz University,

Jeddah, Saudi Arabia.

Email id : HSALQAHTANI@kau.edu.sa

Abstract

Orthodontic treatment can be part of a dental interdisciplinary treatment as a way to help other specialists in the team achieve efficient treatment results when dealing with complex cases. The team members must have basic and sufficient knowledge related to other disciplines if they are to have common ground for fruitful discussion of treatment options and possible solutions that will provide optimum esthetics and function, especially for adult patients. This article discusses important factors related to endodontics, periodontics, and restorative/prosthetic and their interactions with orthodontics.

Keywords: interdisciplinary; orthodontics; endodontics, periodontics, prosthodontics

How to Cite This Article: Hamad A, Factors to be Considered in Orthodontic Interdisciplinary Approach – A Review. *Int J Orthod Rehabil* 2022;13:1:10-15

INTRODUCTION

Today, the expectations of dental patients, and especially adults, are increasingly leaning toward functionally and esthetically optimized dental treatment results. Thus, the scope of dentistry is shifting from a single dental specialist to dental teamwork that provides interdisciplinary care. Therefore, a partnership between the orthodontist and other dental specialists, such as the periodontist, oral surgeon, prosthodontist, and endodontist, is often desirable^[1]. An orthodontic interdisciplinary approach mandates working with other dental specialists, and this must be done in a timely manner and should be followed up thoroughly. This interdisciplinary care should be executed efficiently and effectively to provide the patient with significant benefits. A thorough understanding of the basic knowledge related to other specialties is essential for establishing efficient treatment plans and minimizing overall risks to the patients. The orthodontist must remain vigilant and active during interdisciplinary care^[2]. This article discusses the important factors to be considered in the interface between orthodontics and different dental disciplines.

ORTHODONTICS AND ENDODONTICS

Light orthodontic force is usually optimum for producing tooth movement, minimizing dental pulp damage, and enabling any pulpal damage repair during orthodontic movement^[3]. The occurrence of dental pulp obliteration and/or necrosis after orthodontic movement can indicate a past history of dental trauma as the causative factor, and this requires thorough investigation. Moreover, teeth that have undergone severe traumatic injury are more susceptible to

pulp necrosis and/or root resorption when subjected to orthodontic treatment, and these risks have to be explained to the patient before starting orthodontic treatment^[4].

During orthodontic treatment, traumatically injured teeth must be evaluated radiographically every 3 months to assess the status of root resorption. These teeth should not be used as anchorage teeth or be subjected to excessive movements, such as intrusion. Consideration of a resting period after trauma is important before starting orthodontic movement. The current recommendation is to wait 3 to 4 months before commencing orthodontic movement in cases of mild trauma, including subluxation and concussion. A one-year wait time is advisable for teeth with moderate trauma (luxation) and two years for teeth with severe trauma, such as root fracture and reimplantation^[5,6]. In cases where surgical endodontic treatment is needed during orthodontic treatment, the orthodontist should pause the treatment for at least 6 months after the surgery to allow periapical healing and to ensure proper tooth stability^[7].

Teeth with proper endodontic treatment can be moved orthodontically in a similar manner to untreated healthy teeth. During orthodontic movement, properly treated teeth were reported to be less susceptible to apical root resorption^[8,9]. The orthodontic movement of an endodontically treated tooth with or without apical periodontitis can start after 15-30 days to allow healing and reorganization of the tissues^[6].

Before starting orthodontic tooth movement, the present recommendation is to complete the endodontic treatment with final obturation material, followed by a good coronal seal. However, teeth with signs of external root resorption should be approached differently. Calcium hydroxide should

be placed for 12 weeks before the final obturation, as this treatment will promote new cementum formation and healing^[10]. For teeth requiring endodontic treatment during the orthodontic treatment, the recommendation is to fill the canals temporarily with calcium hydroxide after cleaning and shaping, and then to maintain the treatment during the active tooth movement. This has to be followed by a final canal obturation after the end of orthodontic treatment. This approach can minimize the risk of external root resorption; however, it is not recommended for teeth that have already undergone successful endodontic treatment prior to orthodontic movement.^[7]

The healing status of endodontically treated teeth has been described in the literature under three categories: healed and normal; asymptomatic and functional; and symptomatic with no healing^[11]. A recent common practice has been to perform orthodontic movement of functional and asymptomatic teeth with periapical lesions that have undergone root canal treatment. Orthodontically moving endodontically treated teeth with apical lesions that are otherwise asymptomatic and functional has no effect on the lesion size^[8]. Therefore, when treating asymptomatic and functional endodontically treated teeth, a practical strategy is to delay the endodontic intervention until completion of the orthodontic treatment to allow for possible late healing and extended follow-up^[12].

Nevertheless, endodontic treatment during orthodontic treatment can be challenging. This is because of isolation issues that arise due to the presence of the orthodontic bands and tubes. Furthermore, lingual brackets might hinder access for cavity preparation, especially in the anterior teeth. Orthodontic attachments might affect the pulp vitality tests, while also reducing the accuracy of radiographic evaluation. Therefore, coordination with the orthodontist is recommended for removal of the bands or brackets before endodontic treatment and replacing them later^[13].

If external root resorption affects an endodontically treated tooth, many scenarios might manifest regarding the remaining root canal filling material. The material might be removed together with the root structure during the resorption process, it might be left behind in the alveolar bone and lead to fibrous tissue formation and/or sinus tract formation, or it might extend beyond the newly formed apical foramen, resulting in pseudo-overfilling, where the apex will be surrounded by a new lamina dura and periodontal ligament space close to the remaining root canal filling^[10]. The orthodontist and other team members, including the endodontist, restorative dentist, and prosthodontist, should have a collaborative and constructive relationship. Once a root canal treatment has been completed but subsequently fails after orthodontic tooth movement, the orthodontic movement should not be blamed for this failure. The failure should be investigated by the other team members to find the causative factor^[14].

Some orthodontic procedures might give rise to endodontic complications. Careless placement of temporary anchorage devices (TADs) very close to or in contact with the roots associated with pulpal injury can lead to pulp necrosis and apical periodontitis. If the periodontal ligament, cementum, or dentin is affected, but without pulpal involvement, repair can occur within 12 weeks after removal of the TADs.

These iatrogenic complications can be avoided by meticulous planning and appropriate procedures^[15]. Teeth with infrabony fractures that cannot be treated solely with crown lengthening procedures to obtain a healthy biologic width should be approached with integrated teamwork. The crown/root ratio and the amount of required extrusion need to be evaluated by the team. Root canal treatment should be commenced before starting orthodontic treatment. A bracket or a button can then be bonded to the remaining crown structure and used to attach the tooth to the main orthodontic arch wire to start the extrusion. In cases where the coronal structure is insufficient, a post space can be prepared inside the canal, followed by cementing a hook or post to aid attachment of the remaining tooth to the main arch wire. Exposure of a great amount of intact tooth structure to obtain a "ferrule effect" should be ensured by conducting a supracrestal fiberotomy, in combination with extrusion, to prevent coronal migration of the gingiva and bone. The fracture resistance of the tooth absolutely requires 1.5–2 mm of sound supragingival tooth structure^[16]. Once the biologic width (around 2 mm) is established, the orthodontic treatment should stop, and the tooth should be stabilized for 6 weeks before restorative treatment^[5,17].

ORTHODONTICS AND PERIODONTICS

Orthodontic treatment does not cause periodontal damage if oral hygiene has been maintained and the gingival inflammation is kept to a minimum. The combination of orthodontic treatment and continuous plaque-induced inflammation is an important causative factor of periodontal breakdown. Orthodontic attachments may interfere with plaque removal, thereby increasing the risk of gingival inflammation^[18]. The position of orthodontic attachments can also have an effect on periodontal tissues; for example, subgingivally placed orthodontic bands and attachments may intrude on the alveolar bone. Furthermore, cases with banded appliances have been reported to be more prone to gingival inflammation, loss of attachment, and gingival hyperplasia with pseudo-pocketing in contrast to the bonded cases^[19,20]. When placing orthodontic brackets, the current recommendation is to align the bracket slots perpendicular to the tooth long axis, rather than parallel to the incisal edges, to minimize the chance of significant divergence of the roots and an unaesthetic open gingival embrasure (black triangle)^[18].

Gingival recession occurs when the gingival margin displaces apically to the cemento-enamel junction, resulting in exposure of the root surface. Orthodontic treatment does not necessarily give rise to gingival recession unless certain factors are present. Tooth movement that occurs outside the surrounding alveolar envelope, a thin cortical plate, thin gingival tissue (thin biotype), and insufficient keratinized gingiva (at least 2 mm) are considered risk factors for gingival recession^[21]. Gingival augmentation procedures, including free gingival grafting, might be beneficial to increase the width of keratinized gingiva, improve plaque control, and minimize gingival inflammation in cases that have insufficient keratinized gingiva and vestibular width^[22].

Adult patients interested in having orthodontic treatment have increased in number, and many of these patients might present with varying degrees of periodontal issues. Labial flaring, drifting, spacing, rotation, and extrusion of teeth

might occur due to compromised periodontal support that cannot stabilize the teeth against external forces. Maxillary incisors are prone to over eruption and pathological migration. Orthodontic treatment can be commenced in cases with periodontal disease, provided that the periodontal condition is under control^[23].

Periodontitis is classified into chronic and aggressive forms^[24]. Chronic periodontitis is the most frequent form among adults over 30 years of age^[25]. It can manifest as localized or generalized chronic periodontitis, based on the percentage of sites affected. If more than 30% of the sites are affected, periodontitis is considered generalized. The amount of plaque and calculus, in addition to other factors (e.g., stress, smoking, uncontrolled diabetes, improper contact points, and unfavorable dental anatomy), are risk factors that affect the intensity of chronic periodontitis. Aggressive periodontitis can manifest as a localized form that starts in adolescence (13–14 years) and causes loss of attachment of the incisors and first molars. It involves no less than 2 permanent teeth, including at least one molar, and it affects no more than 2 teeth beside the incisors and first molars. Since adolescents and young patients represent the majority of patients seen in orthodontic practice, the orthodontist should be able to diagnose and manage these cases effectively with other disciplines^[26,27]. Generalized aggressive periodontitis affects patients in their 30s and causes loss of attachment in no less than 3 permanent teeth beside the incisors and first molars^[27]. The current recommendation for avoiding aggressive periodontitis complications is to perform a quick probing for the key indicator teeth, in addition to assessment of any swelling, pockets, mobility, gingival inflammation, recession, bone loss, and recent signs of tooth migration and mobility. If periodontitis is suspected, the patient should be referred to a periodontist immediately^[28,29]. After active periodontal therapy for aggressive periodontitis, a follow-up for six months is required to assess the case stability before starting orthodontic treatment^[30]. During the orthodontic treatment of cases with stabilized aggressive periodontitis, the anchorage quality of the permanent first molars should be evaluated due to the potential for significant bone loss around them. Thus, careful management of the anchorage is advised, as is consideration of the use of temporary anchorage devices (TAD) to reduce undesirable effects^[31]. If aggressive periodontitis occurs during the orthodontic treatment, the orthodontist should pause the treatment and refer the patient immediately to a periodontist. This might require removal of the orthodontic appliances to aid in periodontal therapy^[32,33]. Factors to be considered in cases with aggressive periodontitis include the use of light wires during leveling and alignment, the use of bonded attachments, the use of steel ligation, the removal of excess composite during bonding, the use of simple orthodontic mechanics, the activation of orthodontic appliances over longer intervals, and the use of a clear vacuum-formed retainer with minimal gingival contact. Furthermore, if the case needs extraction, then the teeth with aggressive periodontitis with the poorest prognosis should be extracted, followed by a waiting period of three months before moving adjacent teeth to prevent their reinvolvement with the disease^[34].

In cases that have a compromised periodontium that is maintained very well and under control, orthodontic treatment can be performed to improve the periodontal

condition, function, and esthetics. Caution is needed, since the periodontal support is reduced, resulting in less resistance to orthodontic forces. Therefore, the orthodontist should precisely control the intensity and direction of the applied forces^[35]. Furthermore, teeth with reduced periodontium have their center of resistance moved apically. Thus, any applied force tends to have a greater moment, and this mandates a large counter-moment to achieve better control of root movement^[36].

Extraction of an unrestorable permanent tooth or the loss of a deciduous tooth with no permanent successor can lead to an edentulous space with a resorbed bony alveolar ridge if left unrestored for a long time. This might also lead to gradual tipping, lingual rolling, rotation of neighboring teeth, over eruption of opposing teeth, bite deepening, unfavorable gingival contours, nonworking side interferences, and pseudo pockets due to apical displacement of the cemento-enamel junction of the tipped teeth^[37]. Orthodontic up righting, with or without space closure, eliminates the pseudo pockets, improves occlusion, allows better access for restorative/prosthetic work, and increases plaque removal efficiency^[23]. Cutting the costs for ridge augmentation and implants makes orthodontic space closure very appealing. Nevertheless, space closure of an old extraction site with a resorbed ridge is challenging, especially in the mandible, due to its denser cortical bone. Attempts to close spaces, if not carefully planned, might result in incomplete space closure, dehiscence, prolonged treatment time, unparallel roots, and possible relapse^[38].

Strategic orthodontic tooth movement can aid in preparing future implant sites by facilitating alveolar bone regeneration and the development of supporting tissues. Cases with a congenital absence of the maxillary lateral incisors can benefit from allowing the canines to erupt close to the central incisors, followed by distalization to allow bone deposition between the central incisors and canines. A similar approach can be taken in cases of congenitally missing second premolars that have vertical alveolar defects or significant ridge resorption. In those cases, the first premolars can be distalized into the second premolar space to allow implant placement at the first premolar location, as this will have better bone quantity and quality^[39].

Advanced periodontal disease might lead to elongation and flaring of the incisors, resulting in a traumatic deep bite. Orthodontic intrusion, as an adjunct to periodontal therapy, can help in treating these incisors. Intrusion can stabilize the dentition, reduce the trauma, improve the smile esthetics, enhance periodontal status, and result in bone deposition in the middle and coronal parts of the root along the stretched part of the periodontal ligament. Light force through the long axis of the tooth and periodic periodontal surveillance and maintenance are factors to be considered during intrusion^[23,40]. In cases of intra-bony defects, which mandate regenerative surgery, the orthodontic movement can be initiated safely 4 weeks after the surgery, provided that periodontal status is under control^[41]. Moreover, orthodontic intrusion can be used to correct the position of over-erupted worn incisors. Long-standing and continuous wear of incisors can lead to coronal migration of the gingival tissues, reduced crown height, over-eruption, a gummy smile, and uneven gingival margins. During orthodontic intrusion, the gingival apparatus tends to follow the apical direction of tooth movement. Therefore, factors to consider in cases of

intrusion of worn incisors are light intrusive forces, possible root resorption that might affect crown-to-root ratio, and possible post-intrusion mucogingival surgery to increase crown length^[23].

Orthodontic extrusion, with or without circumferential supracrestal fiberotomy, can have beneficial effects in cases that require a multidisciplinary approach. This extrusion can be used as an adjunct treatment to improve angular/vertical periodontal defects, reduce pocket depth, modify gingival zenith location, increase the width of keratinized gingiva, facilitate coronal movement of the gingival margin following the direction of tooth movement, correct the papillary contour between adjacent teeth or a tooth and an implant, and develop a future implant site through forced extrusion of hopeless teeth to increase vertical bone quantity. Extrusion can be done slowly, at 1 mm/month, or rapidly, at 1 mm/week, with no damage to the periodontal apparatus. Extrusive forces should not be more than 15 g for anterior teeth and 50 g for posterior teeth. During extrusion, the patient will require evaluation every 1–2 weeks to assess the amount of extrusion, adjust the appliance, and modify the occlusion^[42].

ORTHODONTICS AND RESTORATIVE/ENDODONTICS

The establishment of optimum dental function and esthetics during restorative work might require an orthodontic intervention. A diagnostic wax-up is a good starting point for effective communication to help the orthodontist and prosthodontist visualize and agree on the final tooth position^[43]. Anchorage needs to be planned very thoroughly in adult cases, especially those with multiple missing teeth that need to be moved carefully to distribute or close spaces to facilitate restorative care. TADs and/or dental implants can be utilized for anchorage during orthodontic treatment^[44]. Dental implants can be placed before or during orthodontic treatment, provided that their precise position has been determined beforehand by simulating orthodontic movement using a diagnostic setup for the corrected tooth position and a wax-up for the missing teeth. A surgical guide can then be fabricated to correctly guide the implant placement. Recently, this process has been done efficiently using digital software, which made this process faster and simpler^[45].

A deep bite or over closure in adults can complicate the restoration of anterior teeth and compromise the esthetics and function of the final restorations. One way to increase the vertical dimension of the patient and to provide anterior space for restoration is to build the occlusal surfaces of the posterior teeth with direct or indirect restorations^[46]. Another conservative option is orthodontic intrusion of the anterior teeth, extrusion of the posterior teeth, or combination of both, followed by restorative treatment. Intrusion of the anterior teeth is more stable in adults than posterior extrusion and can be done through segmental mechanics and/or using TADs. However, in cases of severe facial shortening and compromised facial harmony, orthognathic surgery is indicated^[47]. Kokich's approach is recommended to determine which teeth to be intruded either the upper or lower anteriors. A cephalometric x-ray is used to draw the occlusal plane from the point of contact between the upper and lower second molars to the level of the upper lip at rest. Normally, the upper anteriors should extend

occlusally to this line by 2–3 mm in young patients and less in older ones, while the lower anteriors should be at the level of this plane. Any extension of the anterior teeth beyond these limits should be targeted and treated with intrusion^[48]. In addition, the gingival margins of the adjacent anterior teeth, rather than incisal edges, should be evaluated to determine the amount of intrusion required and whether surgical crown lengthening is indicated^[44,49].

Orthodontic intrusion of worn anterior teeth can help the restorative dentist achieve an optimal height and width during restoration of these teeth. The amount of tooth displayed at rest, the lip mobility, and the gingival margins should be evaluated before starting treatment to determine the amount of intrusion required to allow the restorative dentist to restore these teeth incisally. The gingival margins of the adjacent non-worn teeth can be used as a reference to intrude the worn teeth with coronally migrated gingival margins as a way to align the teeth in their proper position before restorations. Alignment of the gingival margins through intrusion will reveal the incisal edge discrepancy, which might require removal of the brackets temporarily to allow the restorative dentist to place temporary restorations with optimal heights, followed by either re-bonding the brackets to continue orthodontic treatment or finishing the orthodontic treatment and stabilizing the case. Retention is recommended for six months to allow reorganization of the periodontal structures and to prevent any vertical dental movements. Note that root resorption can occur with intrusion. Therefore, the restorative dentist should anticipate this and evaluate the resultant future crown/root ratio^[50,51].

CONCLUSION

Interdisciplinary dental care requires good communication between specialists and an understanding of basic knowledge related to other disciplines to achieve optimal treatment results. Orthodontic treatment can be commenced efficiently in cases that have endodontic or periodontic problems, provided that all diseases are treated properly and are well under control. Diagnostic setup and wax-up using a conventional master cast or a virtual set-up through software is crucial during comprehensive prosthodontic planning that needs orthodontic intervention.

CONFLICT OF INTEREST

None

SOURCE OF FUNDING

The author of this review has no funding sources to declare.

REFERENCES

- [1] Groß K, Wolfart S. Interfaces between orthodontics and prosthodontics: interdisciplinary possibilities and "innovations". *German Dental Journal International*. 2020;2:160-7.
- [2] Abdelkarim A, Jerrold L. Strategies for improved interdisciplinary care and communication in orthodontics. *Am J Orthod Dentofacial Orthop*. 2017;152:717-21.
- [3] Vermiglio G, Centofanti A, Matarese G, Militi A, Matarese M, Arco A, et al. *Human Dental Pulp Tissue*

during Orthodontic Tooth Movement: An Immunofluorescence Study. *J Funct Morphol Kinesiol*. 2020;5.

[4] Mustaffa M, Nasir SH. Endodontic-orthodontic interrelationship: a review. *IJUM Journal of Orofacial and Health Sciences*. 2021;2:4-15.

[5] Kapoor P, Singh H. Endodontic-orthodontic Interrelationships: A clinician's guide. *International Journal of Dental and Medical Specialty*. 2020;7:29-31.

[6] Consolaro A, Consolaro RB. Orthodontic movement of endodontically treated teeth. *Dental Press J Orthod*. 2013;18:2-7.

[7] Hamilton RS, Gutmann JL. Endodontic-orthodontic relationships: a review of integrated treatment planning challenges. *Int Endod J*. 1999;32:343-60.

[8] Alqerban A, Almanea A, Alkanhal A, Aljarbou F, Almassen M, Fieuws S, et al. Impact of orthodontic treatment on the integrity of endodontically treated teeth. *Eur J Orthod*. 2019;41:238-43.

[9] Ghaffari S, Ardakani AS, Samadian S, Soleimani M. Evaluate the available evidence regarding orthodontic-induced external root resorption of endodontically treated teeth: Systematic review and meta-analysis. *EurAsian Journal of BioSciences*. 2020;14:7961-6.

[10] Anwar H, Darcey J, Malik OH. The orthodontic/endodontic interface part 4. *Dent Update*. 2018;45:1024-31.

[11] Friedman S, Mor C. The success of endodontic therapy-healing and functionality. *J Calif Dent Assoc*. 2004;32:493-503.

[12] Molven O, Halse A, Frisstad I, MacDonald-Jankowski D. Periapical changes following root-canal treatment observed 20-27 years postoperatively. *Int Endod J*. 2002;35:784-90.

[13] Mohankumar K, Parameshwaran T, Asokan U. An Evidence Based Review of Literature-Effect of Orthodontic Treatment on Endodontically Treated Teeth. *Journal of Advanced Medical and Dental Sciences Research*. 2020;8:156-62.

[14] Consolaro A, Miranda DAO, Consolaro RB. Orthodontics and Endodontics: clinical decision-making. *Dental Press J Orthod*. 2020;25:20-9.

[15] Rossi-Fedele G, Franciscatto GJ, Marshall G, Gomes MS, Dogramaci EJ. Endodontic complications associated with orthodontic temporary anchorage devices: A systematic review of human studies. *Aust Endod J*. 2020;46:115-22.

[16] Cordaro M, Staderini E, Torsello F, Grande NM, Turchi M, Cordaro M. Orthodontic Extrusion vs. Surgical Extrusion to Rehabilitate Severely Damaged Teeth: A Literature Review. *Int J Environ Res Public Health*. 2021;18.

[17] Troiano G, Parente G, Laino L, Dioguardi M, Cervino G, Ciccì M, et al. Use of orthodontic extrusion as aid for

restoring extensively destroyed teeth: a case series. *J Transl Sci*. 2016;2:252-5.

[18] Harshita N, Kamath DG, Kadakampally D. Perio-Ortho Interactions-A Review. *Journal of Pharmaceutical Sciences and Research*. 2018;10:1053-6.

[19] Boyd RL, Baumrind S. Periodontal considerations in the use of bonds or bands on molars in adolescents and adults. *Angle Orthod*. 1992;62:117-26.

[20] Alexander SA. Effects of orthodontic attachments on the gingival health of permanent second molars. *Am J Orthod Dentofacial Orthop*. 1991;100:337-40.

[21] Morris JW, Campbell PM, Tadlock LP, Boley J, Buschang PH. Prevalence of gingival recession after orthodontic tooth movements. *Am J Orthod Dentofacial Orthop*. 2017;151:851-9.

[22] Orsini M, Benloch D, Aranda Macera JJ, Flores K, Ríos-Santos J-V, Pedruelo FJ, et al. Improvement of Periodontal Parameters with the Sole Use of Free Gingival Grafts in Orthodontic Patients: Correlation with Periodontal Indices. A 15-Month Clinical Study. *Int J Environ Res Public Health*. 2020;17:6578.

[23] Antoun JS, Mei L, Gibbs K, Farella M. Effect of orthodontic treatment on the periodontal tissues. *Periodontol* 2000. 2017;74:140-57.

[24] Armitage GC. Development of a classification system for periodontal diseases and conditions. *Ann Periodontol*. 1999;4:1-6.

[25] Eke PI, Dye BA, Wei L, Thornton-Evans GO, Genco RJ, Cdc Periodontal Disease Surveillance workgroup: James Beck GDRP. Prevalence of periodontitis in adults in the United States: 2009 and 2010. *J Dent Res*. 2012;91:914-20.

[26] Bagga DK. Adult orthodontics versus adolescent orthodontics: an overview. *J Oral Health Comm Dent*. 2010;4:42-7.

[27] Kruk H, Bensaid X, Chevalier G, Cherkaoui S, Fontanel F, Danan M. Severe periodontitis and orthodontics: How far should we go? *Int Orthod*. 2018;16:450-62.

[28] Mathews DP, Kokich VG. Managing treatment for the orthodontic patient with periodontal problems. *Semin Orthod*. 1997;3:21-38.

[29] Levin L, Einy S, Zigdon H, Aizenbud D, Machtei EE. Guidelines for periodontal care and follow-up during orthodontic treatment in adolescents and young adults. *J Appl Oral Sci*. 2012;20:399-403.

[30] Panchal AH, Patel VG, Bhavsar NV, Mehta HV. Orthodontic-periodontic intervention of pathological migration of maxillary anterior teeth in advanced periodontal disease. *J Indian Soc Periodontol*. 2013;17:378-82.

[31] Leung MTC, Lee TCK, Rabie ABM, Wong RWK. Use of miniscrews and miniplates in orthodontics. *J Oral Maxillofac Surg*. 2008;66:1461-6.

[32] Machtei EE, Zubery Y, Katz Y, Goultchin J, Ben-Yehouda A. Multiple therapy approach to juvenile periodontitis: a case report. *Quintessence Int.* 1991;22:365-70.

[33] Sanders NL. Evidence-based care in orthodontics and periodontics: a review of the literature. *J Am Dent Assoc.* 1999;130:521-7.

[34] Gyawali R, Bhattarai B. Orthodontic Management in Aggressive Periodontitis. *Int Sch Res Notices.* 2017;2017:8098154.

[35] Rachala MR, Aileni KR, Kumar PN, Soujanya D, Prathima CR. Orthodontic management of a periodontally compromised patient. *International Journal of Orthodontic Rehabilitation.* 2017;8:78.

[36] Diedrich P, Fritz U, Kinzinger G. Interrelationship between Periodontics and Adult Orthodontics. *Periodontal Practice Today.* 2004;1.

[37] Serindere G, Bolgul B, Parlar T, Cosgun A. Effects of first permanent molar extraction on space changes observed in the dental arch using data mining method. *Niger J Clin Pract.* 2019;22:936-42.

[38] Sabri R. Multidisciplinary management of permanent first molar extractions. *Am J Orthod Dentofacial Orthop.* 2021;159:682-92.

[39] Spear FM, Mathews DM, Kokich VG. Interdisciplinary management of single-tooth implants. *Semin Orthod.* 1997;3:45-72.

[40] Papageorgiou SN, Antonoglou GN, Michelogiannakis D, Kakali L, Eliades T, Madianos P. Effect of periodontal-orthodontic treatment of teeth with pathological tooth flaring, drifting, and elongation in patients with severe periodontitis: A systematic review with meta-analysis. *J Clin Periodontol.* 2021.

[41] Jepsen K, Tietmann C, Kutschera E, Wullenweber P, Jager A, Cardaropoli D, et al. The effect of timing of

orthodontic therapy on the outcomes of regenerative periodontal surgery in patients with stage IV periodontitis: A multicenter randomized trial. *J Clin Periodontol.* 2021;48:1282-92.

[42] Gonzalez-Martin O, Solano-Hernandez B, Gonzalez-Martin A, Avila-Ortiz G. Orthodontic Extrusion: Guidelines for Contemporary Clinical Practice. *Int J Periodontics Restorative Dent.* 2020;40:667-76.

[43] Kokich VG, Spear FM. Guidelines for managing the orthodontic-restorative patient. *Semin Orthod.* 1997;3:3-20.

[44] Kokich VG. Managing complex orthodontic problems: the use of implants for anchorage. *Semin Orthod.* 1996;2:153-60.

[45] Bayraktaroglu HC, Kim JS, Londono J, Baker PS. Digital design of a surgical guide for placement of definitive implants before orthodontic treatment. *J Prosthet Dent.* 2015;114:174-7.

[46] Torbjorner A, Fransson B. Biomechanical aspects of prosthetic treatment of structurally compromised teeth. *Int J Prosthodont.* 2004;17:135-41.

[47] Alfallaj H. Pre-prosthetic orthodontics. *Saudi Dent J.* 2020;32:7-14.

[48] Kokich V. Altering vertical dimension in the perio-restorative patient: the orthodontic possibilities. *Interdisciplinary treatment planning: principles, design, implementation* Chicago: Quintessence Pub, c2008. 2008.

[49] Kokich VG. Esthetics: the orthodontic-periodontic restorative connection. *Semin Orthod.* 1996;2:21-30.

[50] Spear FM. Interdisciplinary Management of Worn Anterior Teeth. *Facially Generated Treatment Planning.* *Dent Today.* 2016;35:104-7.

[51] Kokich VG, Spear F. Interdisciplinary management of anterior guidance: a case report. *Adv Esthet Inter Dent.* 2007;3:2-6.