

Case Report

Epithelial myoepithelial carcinoma arising in a pleomorphic adenoma

Daphne Fonseca, M. Shankari, Chandrasekhara S. Rao¹, Hemanth Kumar Nemade¹

Departments of Pathology and Laboratory Medicine and ¹Surgical Oncology, Basavatarakam Indo-American Cancer Hospital and Research Institute, Hyderabad, Telangana, India

Abstract Epithelial–myoepithelial carcinoma (EMC) is a rare and low-grade malignant tumor of the salivary gland. We present a case of a 37-year-old male with good general condition with swelling in the right preauricular region for the past 3 years measuring 3 cm × 2 cm with intact facial nerve. This patient had a history of preauricular sinus excision surgery 15 years ago. EMC mostly occurs in elderly females. Rarity of our case is in the fact that it has occurred in a middle-aged male with histologic evidence of preexisting pleomorphic adenoma.

Keywords: Epithelial–myoepithelial carcinoma, parotidectomy, pleomorphic adenoma

Address for correspondence: Dr. Daphne Fonseca, Department of Pathology and Laboratory Medicine, Basavatarakam Indo-American Cancer Hospital and Research Institute, Banjara Hills, Hyderabad - 500 034, Telangana, India.
E-mail: daf_doc_2005@hotmail.com

Submitted: 13-May-2020, **Revised:** 22-Sep-2020, **Accepted:** 02-Jan-2021, **Published:** 28-May-2021

INTRODUCTION

Epithelial myoepithelial carcinoma (EMC) is a rare malignant salivary gland tumor with biphasic pattern accounting for nearly 2% of malignant salivary gland tumors and less than 1% of all salivary gland epithelial neoplasm.

CASE REPORT

A 37-year-old male presented with a swelling in the parotid region measuring 3 cm × 2 cm with intact facial nerve and with a history of preauricular sinus excision surgery 15 years ago and presented to our outpatient department with fine-needle aspiration report of a malignant salivary gland neoplasm. Following relevant preoperative investigations, a surgically excised parotidectomy specimen with wide margins was obtained. Cut section of the specimen showed gray-white relatively circumscribed

nodular tumor. Histopathological examination showed low-grade minimally infiltrative multinodular tumor with biphasic differentiation comprising ductal epithelial cells and clear myoepithelial cells. Periphery of the tumor showed chondroid and myxomatous stroma and tubular structures reminiscent of pleomorphic adenoma (PA). Also seen was rim of compressed normal salivary gland tissue. On immunohistochemistry (IHC), epithelial cells showed immunoreactivity to cytokeratin 7 and epithelial membrane antigen (EMA), with Ki-67 of 10%–12%, and myoepithelial cells were highlighted by S-100 and smooth muscle actin (SMA) [Figure 1].

DISCUSSION

EMC is a rare malignant salivary gland tumor with biphasic pattern.^[1] It accounts for nearly 2% of malignant salivary

This is an open access journal, and articles are distributed under the terms of the Creative Commons Attribution-NonCommercial-ShareAlike 4.0 License, which allows others to remix, tweak, and build upon the work non-commercially, as long as appropriate credit is given and the new creations are licensed under the identical terms.

For reprints contact: WKHLRPMedknow_reprints@wolterskluwer.com

How to cite this article: Fonseca D, Shankari M, Rao CS, Nemade HK. Epithelial myoepithelial carcinoma arising in a pleomorphic adenoma. *Int J Head Neck Pathol* 2019;2:33-5.

Access this article online	
Quick Response Code:	Website: www.ijhnp.org
	DOI: 10.4103/JHNP.JHNP_8_20

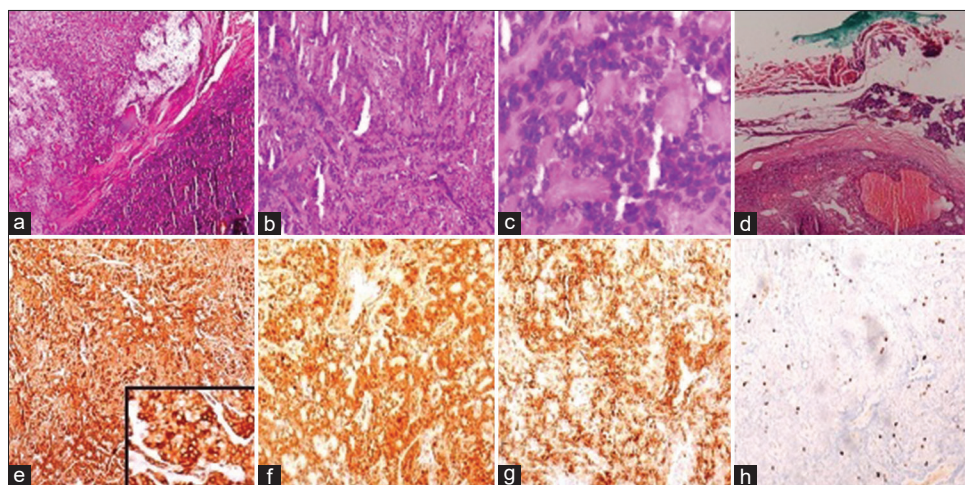


Figure 1: (a) Tumor with peripheral chondromyxoid stroma (H and E, $\times 4$); (b) Tumor arranged in tubules and cords (H and E, $\times 10$); (c) Neoplastic cells with eosinophilic cytoplasm and hyperchromatic nucleus (H and E, $\times 4$); (d) Normal salivary gland parenchyma at the periphery with inked margin (H and E, $\times 10$); (e) cytokeratin 7 showing strong and diffuse positivity (IHC, $\times 10$; inset: $\times 40$); (f) S-100 highlighting the myoepithelial cells (IHC, $\times 10$); (g) smooth muscle actin highlighting the myoepithelial cells (IHC, $\times 10$); (h) Ki-67 with 10%–12% (IHC, $\times 10$)

gland tumors and less than 1% of all salivary gland epithelial neoplasm. They have a predilection for parotid gland followed by submandibular and minor salivary glands.^[1]

EMC is a low-grade malignancy with a recurrence rate of 30%–50%, with chances of lymph node metastases being 15%–20% and 5-year and 10-year survival rates of 80%–94% and 72%–90%, respectively.^[1,2]

Imaging by computerized tomography or magnetic resonance imaging is nonspecific and cannot differentiate EMC from other parotid neoplasms.^[3]

Salivary gland tumors with myoepithelial differentiation such as adenoid cystic carcinoma (ACC), PA, myoepithelioma, basal cell adenoma (BCA), basal cell adenocarcinoma (BCAC), and myoepithelial carcinoma are to be considered in the differential diagnoses. Specific histologic features and IHC are useful to some extent in discriminating these entities from EMCs. On IHC, epithelial component is highlighted by keratins and EMA and myoepithelial component by S-100, SMA, p63, calponin, and Caldesmon. MYB in ACC, PLAG1 in PA, β catenin nuclear reactivity in BCA/BCAC are the characteristic findings. Prevalence of preexisting PA in an EMC ranges from 1.6% to 80%. Our case had histologic evidence of chondromyxoid and hyalinized areas which confirmed the same.^[1,3,4]

HRAS mutations are a common tumorigenic event regardless of anatomic site and have been implicated in 29%–80% of EMCs. HRAS mutations do not show significant correlation with histologic variants or with features of tumor aggressiveness such as nuclear grade,

lymphovascular or perineural invasion, presence of necrosis, mitotic count, or Ki-67 labeling index. Literature review shows the absence (or low prevalence) of HRAS mutations in EMC ex PA as compared to *de novo* EMC.^[1,2]

Next-generation sequencing studies have demonstrated the existence of SMARCB1, FBXW7, and TP53 mutations in addition to HRAS, PIK3CA, and AKT1 in EMCs. However, they are hypothesized to be nonrecurrent and not primary driver mutations and mostly seen in high-grade cases.^[1]

Surgical excision with wide margins followed by radiotherapy is the treatment of choice in tumors larger than 4 cm.^[3]

Follow-up of our patient following parotidectomy with wide margins has been uneventful till date.

Declaration of patient consent

The authors certify that they have obtained all appropriate patient consent forms. In the form the patient(s) has/have given his/her/their consent for his/her/their images and other clinical information to be reported in the journal. The patients understand that their names and initials will not be published and due efforts will be made to conceal their identity, but anonymity cannot be guaranteed.

Financial support and sponsorship

Nil.

Conflicts of interest

There are no conflicts of interest.

REFERENCES

1. El Hallani S, Udager AM, Bell D, Fonseca I, Thompson LD, Assaad A,

Fonseca, *et al.*: Epithelial myoepithelial carcinoma arising in a pleomorphic adenoma

- et al.* Epithelial-myoepithelial carcinoma: Frequent morphologic and molecular evidence of preexisting pleomorphic adenoma, common HRAS mutations in PLAG1-intact and HMGA2-intact cases, and occasional TP53, FBXW7, and SMARCB1 alterations in high-grade cases. *Am J Surg Pathol* 2018;42:18-27.
2. Urano M, Nakaguro M, Yamamoto Y, Hirai H, Tanigawa M, Saigusa N, *et al.* Diagnostic significance of HRAS mutations in epithelial-myoepithelial carcinomas exhibiting a broad histopathologic spectrum. *Am J Surg Pathol* 2019;43:984-94.
 3. Badge SA, Gangane NM, Shivkumar VB, Sharma SM. Epithelial myoepithelial carcinoma of the parotid gland. *Med J DY Patil Univ* 2015;8:772-4
 4. Seifert G, Brocheriou C, Cardesa A, Eveson JW. WHO International Histological Classification of Tumours. Tentative Histological Classification of Salivary Gland Tumours. *Pathol Res Pract.* 1990;186:555-81.