

Case Report

Oral squamous cell carcinoma with myiasis

Sakshi Gupta, Arjun Agarwal¹, Cheena Garg², K. Y. Giri, Archana Chaurasia

Department of Oral and Maxillofacial Surgery, Institute of Dental Sciences, Departments of ¹Surgical Oncology and ²Pathology, Rohilkhand Medical College and Hospital, Bareilly, Uttar Pradesh, India

Abstract

Myiasis is a rare condition that occurred with advanced ulcerated lesions of the oral cavity caused by the larvae in human tissue that evolve to a parasite and is commonly found in tropical countries. Poor oral hygiene is a primary cause for the growth of maggots leading to the development of myiasis. These cases are reported with chief complaint of pain and irritation in a localized area and diagnosed clinically based on the presence of the maggots. Treatment option is manual removal of maggots to cure the inflammatory process and prevent secondary infections. Here, we present a case of oral squamous cell carcinoma with myiasis diagnosed in a 50-year-old female patient.

Keywords: Myiasis, oral, squamous cell carcinoma

Address for correspondence: Dr. Arjun Agarwal, Department of Surgical Oncology, Rohilkhand Medical College and Hospital, Bareilly, Uttar Pradesh, India. E-mail: arjunbly@hotmail.com

INTRODUCTION

The most common type of cancer found in the oral cavity is squamous cell carcinoma, which forms >90% of all oral malignancies.^[1] Advanced cancers infiltrate and destroy tissues, thereby causing disfigurement, loss of function, pain, bleeding, and necrosis.^[2] A rare complication of advanced squamous cell carcinoma is myiasis.^[3]

Myiasis is a term derived from the Greek word “myia,” meaning invasion of vital tissues of humans or other mammals by fly larvae.^[4] F. W. Hope in 1840 coined the term “myiasis,” to refer to diseases of human originating specifically with dipterous larvae as opposed to those, caused by insect larvae in general scholechiasis.^[5] Clinically, myiasis is classified as either primary or secondary. Primary myiasis is rare in humans and is caused by biophagous larvae that feed on living tissue. Secondary myiasis is caused by the necrobiophagous flies that feed on necrotic tissue. Secondary myiasis is the more common type and attacks patients with necrotic cavity lesions.^[6]

In humans, the most commonly affected sites are the skin, nose, ears, eyes, anus, vagina, and oral cavity.^[7] Laurence in 1909 first described oral myiasis, as a rare entity, and is mostly dependent on medical and anatomical conditions, such as neglected mandibular fracture, lip incompetence, cerebral palsy, mouth breathing, anterior open bite, dental extractions, patients undergoing mechanical ventilation, and cancrum oris.^[5] Other predisposing factors are anterior open bite, severe halitosis, poor oral hygiene, ulcerative lesions, and oral malignancies.^[5,8,9] Myiasis is a rare complication of cancerous lesions.^[1]

CASE REPORT

A 50-year-old female patient reported to us with chief complaints of pain and irritation in the left cheek region with foul pungent smell and worms crawling out of the wound present on the left cheek region. Pain was continuous in nature and moderate in intensity. The

Access this article online	
Quick Response Code:	Website: www.ijhnp.org
	DOI: 10.4103/JHNP.JHNP_15_18

This is an open access journal, and articles are distributed under the terms of the Creative Commons Attribution-NonCommercial-ShareAlike 4.0 License, which allows others to remix, tweak, and build upon the work non-commercially, as long as appropriate credit is given and the new creations are licensed under the identical terms.

For reprints contact: reprints@medknow.com

How to cite this article: Gupta S, Agarwal A, Garg C, Giri KY, Chaurasia A. Oral squamous cell carcinoma with myiasis. *Int J Head Neck Pathol* 2018;1:52-4.

patient gives a personal history of chewing pan for the past 30 years. There was no significant medical and dental history. On examination, an ulceroproliferative growth of 4.5 cm × 3.5 cm in the left cheek was seen with necrosis at the center and erythema at margins. Growth was hard and fixed in consistency with communication to the oral cavity and maxillary antrum. Maggots were present in the lesion which became more evident after turpentine oil treatment [Figure 1]. Intraorally, the lesion extended from angle of mouth to retromolar trigone and from upper gingivobuccal sulcus to lower gingivobuccal sulcus. On the basis of clinical examination, our provisional diagnosis was malignancy of the left buccal mucosa with myiasis was made. An orthopantomogram was advised which reveals an ill-defined radiolucency seen on the left lower mandibular posterior teeth region, anterior border of ramus of mandible, and maxillary tuberosity area [Figure 2]. The punch biopsy was suggestive of well-differentiated squamous cell carcinoma [Figure 3a-c]. The patient was

treated with manual removal of maggots with tweezers followed by turpentine oil (12%) instillation into the lesion for 20 min [Figure 3d]. Wound was then irrigated with hydrogen peroxide and normal saline for 3 days and tablet ivermectin (6 mg/day) systemically for 3 days. After 3 days, there was no evidence of maggots [Figure 4] and the patient is now undertaking palliative radiotherapy using the external beam radiation technique.

DISCUSSION

Myiasis with squamous cell carcinoma is a very rare condition.^[1] Myiasis is diagnosed by observing the larvae in the central punctum of the lesion.^[10] The maggots scrape away the tissues and lacerate the fine blood vessels while feeding.^[3] During feeding from necrotic or living tissue, the caudal ends of the maggots remain visible at

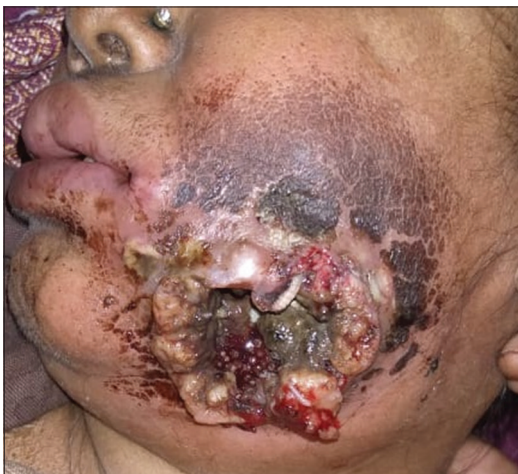

Figure 1: Preoperative picture of lesion on the left cheek region presents ulceroproliferative lesion with maggots

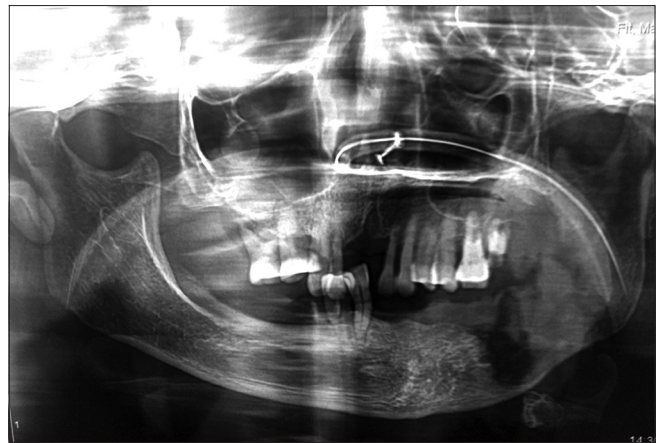

Figure 2: Orthopantomogram reveals, an ill-defined radiolucency seen on the left lower mandibular posterior teeth region, anterior border of ramus of mandible, and maxillary tuberosity area, missing teeth in relation to 14, 15, 12, 11, 21, 32, 33, 34, 35, 36, 37, 42, 43, 44, 45, 46, and 47 with chronic generalized periodontitis

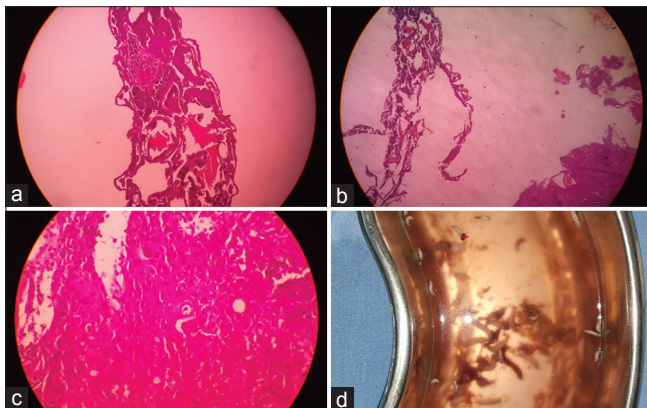


Figure 3: (a) Histopathological picture of maggot. (b) Histological picture of maggots with squamous cell carcinoma. (c) Histological picture of squamous cell carcinoma. (d) Picture shows manually removed maggots from the lesion

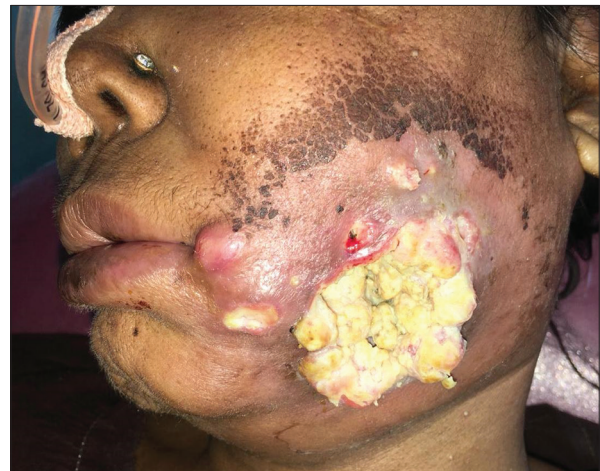

Figure 4: This is the picture of the lesion after 3 days of treatment, there was no evidence of maggots in the lesion

the surface of the lesion. Extension into surrounding tissues may occur and can cause tissue destruction and morbidity.^[10] Hemorrhage from the lesion is severe and the surrounding tissue becomes tense, edematous, emitting characteristic foul-smelling lesion.^[3] The treatment is based on local disinfection using turpentine oil, hydrogen peroxide and normal saline, and mechanical removal of the larvae. Recently, a systemic therapy with tablet ivermectin (6 mg/day), a semi-synthetic macrolide antibiotic, has been used for the treatment of oral myiasis, but removal of the parasite is essential to cure the inflammatory process and prevent secondary infections. Flushing the wound with nitrofurazone has also been suggested to cause an anaerobic environment to the larvae.^[11] The disease should be prevented by controlling fly population, cleaning and covering the wounds, and by educating the susceptible population to maintain good oral and personal hygiene.^[1]

In this case, we treated the lesion with pouring 12% of turpentine oil on the maggots, manual removal of maggots followed by irrigation with 6.7% of hydrogen peroxide and 2% of normal saline, and tablet ivermectin (6 mg/day) was prescribed for 3 days and nasogastric tube was inserted into the patient for feeding because the food was being expelled from the cancerous ulcer. All the maggots were manually removed and the lesion was dressed using gauze pads. After 3 days, there was no evidence of maggots and the patient is now undertaking for palliative radiotherapy using external beam radiation.

Declaration of patient consent

The authors certify that they have obtained all appropriate patient consent forms. In the form the patient(s) has/have given his/her/their consent for his/her/their images and

other clinical information to be reported in the journal. The patients understand that their names and initials will not be published and due efforts will be made to conceal their identity, but anonymity cannot be guaranteed.

Financial support and sponsorship

Nil.

Conflicts of interest

There are no conflicts of interest.

REFERENCES

1. Al-Maweri SA, Al-Sufyani GA, Tarakji B, Abdulrab S. Myiasis associated with oral squamous cell carcinoma – A literature review. *Asian Pac J Cancer Prev* 2015;16:4997-9.
2. Ferlay J, Shin HR, Bray F, Forman D, Mathers C, Parkin DM. Estimates of worldwide burden of cancer in 2008: GLOBOCAN 2008. *Int J Cancer* 2010;127:2893-917.
3. Gopalakrishnan S, Srinivasan R, Saxena SK, Shanmugapriya J. Myiasis in different types of carcinoma cases in Southern India. *Indian J Med Microbiol* 2008;26:189-92.
4. Pereira T, Tamgadge AP, Chande MS, Bhalerao S, Tamgadge S. Oral myiasis. *Contemp Clin Dent* 2010;1:275-6.
5. Bhagawati B, Gupta M, Singh S. Oral myiasis: A rare entity. *Eur J Gen Dent* 2013;2:312-4.
6. Antunes AA, Santos Tde S, Avelar RL, Martins Neto EC, Macedo Neres B, Laureano Filho JR. Oral and maxillofacial myiasis: A case series and literature review. *Oral Surg Oral Med Oral Pathol Oral Radiol Endod* 2011;112:e81-5.
7. Saravanan T, Mohan MA, Thinakaran M, Ahammed S. Oral myiasis. *Indian J Palliat Care* 2015;21:92-4.
8. Sankari LS, Ramakrishnan K. Oral myiasis caused by *Chrysomya bezziana*. *J Oral Maxillofac Pathol* 2010;14:16-8.
9. Aggarwal A, Daniel MJ, Shetty RS, Kumar BN, Sumalatha CH, Srikanth E, et al. Oral myiasis caused by *Chrysomya bezziana* in anterior maxilla. *Case Rep Dent* 2014;2014:518427.
10. Thomas S, Nair P, Hegde K, Kulkarni A. Nasal myiasis with orbital and palatal complications. *BMJ Case Rep* 2010;2010. pii: bcr0820103219.
11. Pessoa L, Galvão V. Myiasis infestation in advanced oral squamous cell carcinoma. *BMJ Case Rep* 2011;2011. pii: bcr0420114124.