

## Case Report

# Fibroepithelial polyps of the head and neck

Ramiya Ramachandran Kaipuzha, Davis Thomas Pulimoottil, Satvinder Singh Bakshi,  
Suriyanarayanan Gopalakrishnan

Department of ENT and Head and Neck Surgery, Mahatma Gandhi Medical College and Research Institute, Sri Balaji Vidyapeeth,  
Puducherry, India

### Abstract

Fibroepithelial polyps are benign polypoid lesions arising from the mesodermal tissue and are one of the most common cutaneous lesions, but are rare in the oral cavity and upper airway. Two cases are discussed here. A 40 year old male presented with cough of five months duration associated with an intermittent foreign body sensation in the throat. Examination revealed single smooth pinkish pedunculated mass hanging freely from the superior pole of the left tonsil. The patient underwent tonsillectomy and histopathological examination revealed features of fibroepithelial polyp. A 65 year old male chronic smoker presented with swelling in the mouth behind the upper teeth since two months. Examination of the oral cavity revealed a single, non-tender, firm, smooth pedunculated pink swelling just behind the upper incisor on the right side of hard palate; the mass was excised and found to be a fibroepithelial polyp. The diagnosis of fibroepithelial polyps is primarily by histopathological examination of the excised mass. The key to preventing the recurrence of that lesion is its surgical excision *in toto* along with elimination of the source of irritation that led to the lesion.

**Keywords:** Fibroepithelial polyps, hard palate, oral cavity, oropharynx, tonsil

**Address for correspondence:** Dr. Satvinder Singh Bakshi, House Number B2, Shree Pushpa Complex, 15<sup>th</sup> Bharathi Street, Ananda Nagar, Puducherry - 605 009, India.  
E-mail: [saty.bakshi@gmail.com](mailto:saty.bakshi@gmail.com)

### INTRODUCTION

A fibroepithelial polyp is a benign lesion of mesodermal origin and is one of the most common cutaneous lesions but is rarer in the head and neck region. The estimated prevalence of fibroepithelial polyps is 1.2% with a male predilection.<sup>[1]</sup> Chronic inflammatory process has been suggested in the etiology of fibroepithelial polyp. Fibroepithelial polyps may have congenital, infectious, and traumatic origins.<sup>[2]</sup> The skin and genitourinary tract are common sites for fibroepithelial polyps. Fibroepithelial polyps in the head and neck region are documented in the external auditory canal, nasal cavity, oropharynx, epiglottis, hypopharynx, trachea, and bronchus.<sup>[3,4]</sup> Here we discuss two rare cases of fibroepithelial polyps of the tonsil and hard palate.

### CASE REPORTS

#### Case report I

A 40-year-old male presented to the Outpatient Department of the Department of Otorhinolaryngology of a tertiary care centre with complaints of slowly progressive dry irritative cough of five months duration associated with an intermittent foreign body sensation in the throat. There were no symptoms of regurgitation, odynophagia or dysphagia. General and systemic examination was grossly normal. Examination of the oral cavity was normal, while examination of the oropharynx revealed bilateral grade 2 enlargement with a single smooth pinkish pedunculated

This is an open access journal, and articles are distributed under the terms of the Creative Commons Attribution-NonCommercial-ShareAlike 4.0 License, which allows others to remix, tweak, and build upon the work non-commercially, as long as appropriate credit is given and the new creations are licensed under the identical terms.

**For reprints contact:** [reprints@medknow.com](mailto:reprints@medknow.com)

**How to cite this article:** Kaipuzha RR, Pulimoottil DT, Bakshi SS, Gopalakrishnan S. Fibroepithelial polyps of the head and neck. *Int J Head Neck Pathol* 2018;1:24-7.

Access this article online	
Quick Response Code:	Website: <a href="http://www.ijhnp.org">www.ijhnp.org</a>
	DOI: 10.4103/JHNP.JHNP_4_18

mass of size approximately 1 × 2 cm seen hanging freely from the superior pole of the left tonsil [Figure 1.1]. On palpation, the mass was soft in consistency, and did not bleed on touch. It moved freely during swallowing and coughing and there was no induration surrounding its attachment. Examination of the ears and nose were normal. With a differential diagnosis of tonsillar cyst or oropharyngeal benign polyp, the patient was taken up for tonsillectomy with excision of the mass under general examination. The excised mass [Figure 1.2] was sent for histopathological examination which revealed a polypoidal mass lined by stratified squamous epithelium with a fibrous stroma showing mild lymphocytic infiltration and few blood vessels [Figure 1.3]. These features were suggestive of a fibroepithelial polyp. At one year follow up, the patient is asymptomatic with no signs of recurrence [Figure 1.4].

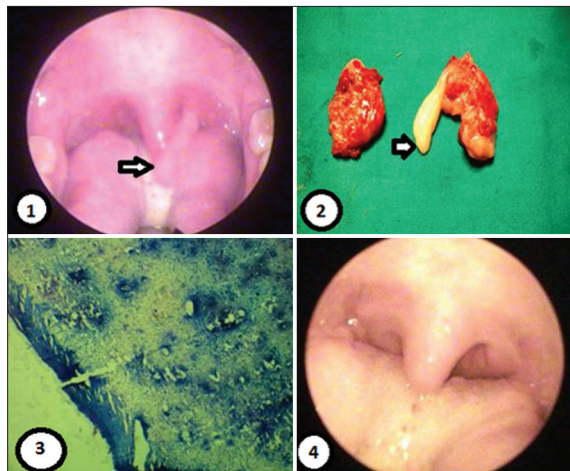
### Case report II

A 65 year old male chronic smoker presented to the outpatient department with complaints of a swelling in the mouth behind the upper teeth since two months which was causing a disturbance during swallowing. General and systemic examination was normal. Local examination of the oral cavity revealed a single, firm, smooth pedunculated pink swelling of size 1 × 1 cm just behind the upper incisor on the right side of hard palate, which was non-tender and firmly attached with a narrow pedicle [Figure 2.1]. Examination of the oropharynx, ears and nose were all normal. Fine needle aspiration cytology examination of the mass showed a hemorrhagic smear and was non-diagnostic. The patient underwent excision

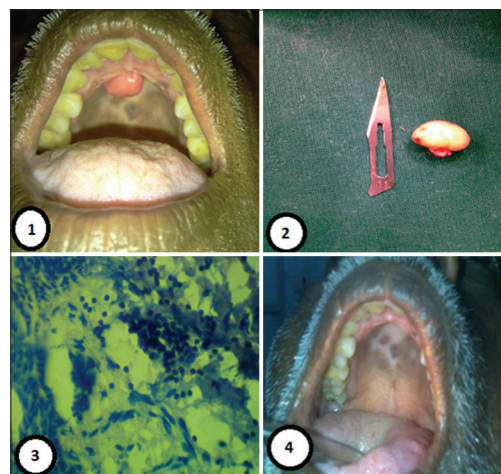
of the mass and the specimen [Figure 2.2] was sent for histopathological examination which showed tissue lined by atrophic keratinized stratified squamous epithelium with subepithelial fibrous infiltrate accompanied by hyalinization with very few capillaries [Figure 2.3]. There was no evidence of malignancy. The histopathological features were suggestive of fibroepithelial polyp of the hard palate. The patient was followed upto 18 months when the patient was still asymptomatic and free of recurrence [Figure 2.4].

### DISCUSSION

Polyps of the upper digestive tract are classified according to their predominant histological components and include fibroma, fibromyxoma, fibrolipoma, angioliipoma or fibroepithelial polyps. Fibroepithelial polyps of the pharynx and upper airways are rare in medical literature. Fibroepithelial polyps are benign polypoid lesions arising from the mesodermal tissue and composed of varying amounts of stroma covered by squamous epithelium and is one of the most common cutaneous lesions. Fibroepithelial polyps are thought to have a prevalence of approximately 12 per 1000 population, with a male predisposition, mostly affecting males between 40 and 70 years of age. They are benign lesions with an extremely low incidence of malignancy. They can vary significantly in size. It is generally an incidental finding on the skin of the neck, trunk, or face and is also known as fibroma or acrochordon, representing a nonspecific and benign growth pattern as opposed to a specified entity. In addition to the skin, fibroepithelial polyp infrequently occurs in the ureteropelvic system, genitals,



**Figure 1:** (1) Shows a single smooth pinkish pedunculated mass of size approximately 1 cm × 2 cm seen hanging freely from the superior pole of the left tonsil; (2) is the post-tonsillectomy specimen showing the attachment of the polyp to the superior pole of the left tonsil; (3) histopathology showing a polypoidal mass lined by stratified squamous epithelium with a fibrous stroma showing mild lymphocytic infiltration and few blood vessels; (4) Postoperative appearance of the oropharynx at 2 months follow up



**Figure 2:** (1) Showing a single, firm, smooth pedunculated pink swelling of size 1 cm × 1 cm just behind the upper incisor on the right side of hard palate; (2) showing the excised gross specimen; (3) histopathology showing tissue lined by atrophic keratinized stratified squamous epithelium with subepithelial fibrous infiltrate accompanied by hyalinization with very few capillaries; (4) Postoperative appearance of the oral cavity at 1 month follow up

or bronchus. Cases of fibroepithelial polyp occurring independently in the head and neck area are rare, and the sites include the oropharynx, tongue, inferior nasal turbinate and external auditory canal.<sup>[4,5]</sup>

Etiology of fibroepithelial polyp is unknown. There are a few theories regarding the cause of these tumours. The first one is a theory of development secondary to focal losses of elastic tissue, but there is inadequate proof to support this hypotheses.<sup>[6]</sup> The second theory is that fibroepithelial polyp is a mixture of different tissue elements which could represent hamartoma of the lamina propria that slowly enlarge or a fibroma that exhibits the features of a benign lesion.<sup>[7]</sup> A prevalence of malignancy in lesions clinically diagnosed as fibroepithelial polyps is extremely low. Traditionally, fibroepithelial polyps have been thought to occur after mucosal trauma.<sup>[8]</sup>

Pharyngeal polyps are rarely symptomatic, and when present, the symptoms vary according to the site of origin. Globus pharyngeus is the usual presentation. The previously reported large polyps originating in the nasopharynx or oropharynx were accompanied by choking, respiratory distress, and coughing of abnormal tissue masses. Furthermore, chronic bleeding from the polyp can occur, resulting in iron deficiency anaemia. Although usually not life-threatening, fibroepithelial polyps of the pharynx may present as an acute medical emergency, causing upper airway obstruction. Management involves first securing the airway.<sup>[7]</sup>

The presence of fibroepithelial polyps in the oral cavity may hinder or obstruct the insertion of an oral prosthesis, cause difficulty with mastication or speech, or even cause bleeding and ulceration following a secondary infection, and these polyps usually occur as a result of trauma or chronic irritation. An important feature of a traumatic fibroma is that it exhibits two different patterns of collagen arrangement, a radiating pattern and a circular pattern, depending on the amount of irritation and the site of the lesion. A radiating pattern is associated with sites that are immobile in nature (*e.g.* the hard palate) and with more severe trauma, while a circular pattern is associated with sites that are flexible in nature (*e.g.* the cheeks) and with less severe trauma, but a true fibroma exhibits neither of those patterns.<sup>[8-10]</sup>

The differential diagnosis for fibroepithelial polyp included fibroma, mucocele, giant cell fibroma, peripheral giant cell granulomas, lymphangiomas, lymphangioma, juvenile angiofibroma and squamous papilloma in the oral cavity including tonsil.<sup>[10]</sup> Surgical excision is the treatment

of choice. In addition to surgery, other treatment modalities are electrocautery, an Nd:YAG laser, a flashlamp-pumped pulsed dye laser, cryosurgery, intralesional injection of ethanol or corticosteroids, and sodium tetradecyl sulfate sclerotherapy.<sup>[10]</sup> However, the crucial step is to examine the tissue histopathologically in order to distinguish a fibro-epithelial polyp from a malignant tumor since those polyps mimic the clinical features of a true fibroma. Recurrence rates are low and recurrence is mostly caused by repetitive trauma at site of the lesion.<sup>[10]</sup>

## CONCLUSION

Diagnosis of an inflammatory hyperplastic lesion is quite difficult for clinicians since all lesions exhibit overlapping clinical features. Recurrence or risk of malignant transformation is extremely rare and diagnosis is primarily by histopathological examination. The key to preventing the recurrence of that lesion is its surgical excision *in toto* along with elimination of the source of irritation that led to the lesion.

## Declaration of patient consent

The authors certify that they have obtained all appropriate patient consent forms. In the form the patient(s) has/have given his/her/their consent for his/her/their images and other clinical information to be reported in the journal. The patients understand that their names and initials will not be published and due efforts will be made to conceal their identity, but anonymity cannot be guaranteed.

## Financial support and sponsorship

Nil.

## Conflicts of interest

There are no conflicts of interest.

## WHY THIS CASE IS BEING REPORTED?

Identification and appropriate management of fibroepithelial polyps of the oropharynx and oral cavity requires a multidisciplinary approach with histopathological examination being the key into diagnosis of these lesions.

## REFERENCES

1. Bouquot JE, Gundlach KK. Oral exophytic lesions in 23,616 white Americans over 35 years of age. *Oral Surg Oral Med Oral Pathol* 1986;62:284-91.
2. Hussein AA, Darwazeh AM, Al-Jundi SH. Prevalence of oral lesions among Jordanian children. *Saudi J Oral Sci* 2017;4:12-7.
3. Li M, Zhang G, Peng A, Wang C. Bronchial fibroepithelial polyp: A case report and review of the literature. *Intern Med* 2013;52:373-6.
4. Tanaka N, Matsunobu T, Shiotani A. Fibroepithelial polyp of the external auditory canal: A case report and a literature review. *Case Rep Otolaryngol* 2013;2013:818197.
5. Lloyd S, Lloyd J, Dhillon R. Chondroid metaplasia in a fibroepithelial

Kaipuzha, *et al.*: Fibroepithelial polyps

- polyp of the tongue. J Laryngol Otol 2001;115:681-2.
6. Mangar W, Jiang D, Lloyd RV. Acute presentation of a fibroepithelial pharyngeal polyp. J Laryngol Otol 2004;118:727-9.
7. Farboud A, Trindade A, Harris M, Pfeiderer A. Fibroepithelial polyp of the tonsil: Case report of a rare, benign tonsillar lesion. J Laryngol Otol 2010;124:111-2.
8. Patil S, Rao RS, Sharath S, Agarwal A. True fibroma of alveolar mucosa. Case Rep Dent 2014;2014:904098.
9. Bataineh A, Al-Dwairi ZN. A survey of localized lesions of oral tissues: A clinicopathological study. J Contemp Dent Pract 2005;6:30-9.
10. Halim DS, Pohchi A, Pang EE. The prevalence of fibroma in oral mucosa among patient attending USM dental clinic year 2006-2010. Indones J Dent Res 2010;1:61-6.