

# Cone beam computed tomography and detection of periodontal bone defects in patients with advanced periodontal disease indicated for periodontal surgeries

Abhishek Singh Nayyar

Department of Oral Medicine and Radiology, Post-Graduate Research Institute, Saraswati-Dhanwantari Dental College and Hospital, Parbhani, Maharashtra, India

## Abstract

**Context and Aim:** Radiographs play an important role in periodontal diagnosis; however, one of the major limitations of the conventional radiological procedures is the presence of considerable overlapping of the overlying anatomical structures and lack of a clear three-dimensional information. Surgical exposure, although being able to evaluate the type and depth of the defect during surgery, provides very little time to the surgeon to plan for the type of procedure required for periodontal regeneration based on the information obtained during surgery. Recently, cone beam computed tomography (CBCT) has emerged as a lower cost alternative to the computed tomography (CT) with high-quality images and lower radiation exposure to the patients, though, *in vivo* studies, in this regard, are still scarce. The aim of the present study was to assess the efficacy of CBCT in the detection of periodontal bone defects in patients with advanced periodontal disease indicated for periodontal surgeries.

**Materials and Methods:** The present cross-sectional study included patients with advanced periodontal disease indicated for periodontal surgeries. Bone defects were measured first with the help of CBCT software and then, during a surgical intervention using the standardized UNC-15 periodontal probe and compared.

**Statistical Analysis:** Statistical analysis was done using SPSS version 18.0 (SPSS Inc., Chicago, IL, USA). Both the measurements were compared with the help of Student's *t*-test.  $P < 0.05$  was considered statistically significant while  $P < 0.001$  was considered highly statistically significant.

**Results:** The palatal/lingual sites in anterior teeth which showed a mean CBCT value of 4.0444 mm and mean surgical value of 4.1822 mm revealed the mean difference to be statistically significant along with the distal sites which showed a mean CBCT value of 3.3667 mm and mean surgical value of 3.5217 mm ( $P = 0.001$ ). The values, although in case of posterior teeth, were not found to be statistically significant.

**Conclusion:** From the observations made from the present study, it could be concluded that CBCT provided good accessibility to visualize sites which were otherwise difficult to access during surgery. Furthermore, the bone density/volume could be detected precisely with the CBCT software which was otherwise not possible with the conventional methods.

**Keywords:** Advanced periodontal disease, cone beam computed tomography, periodontal bone defects, periodontal surgeries

**Address for correspondence:** Dr. Abhishek Singh Nayyar, Department of Oral Medicine and Radiology, Post-Graduate Research Institute, Saraswati-Dhanwantari Dental College and Hospital, Parbhani, Maharashtra, India.  
E-mail: [singhabhishekndls@gmail.com](mailto:singhabhishekndls@gmail.com)

Access this article online	
Quick Response Code:	Website: <a href="http://www.ijhnp.org">www.ijhnp.org</a>
	DOI: 10.4103/JHNP.JHNP_9_18

This is an open access journal, and articles are distributed under the terms of the Creative Commons Attribution-NonCommercial-ShareAlike 4.0 License, which allows others to remix, tweak, and build upon the work non-commercially, as long as appropriate credit is given and the new creations are licensed under the identical terms.

**For reprints contact:** [reprints@medknow.com](mailto:reprints@medknow.com)

**How to cite this article:** Nayyar AS. Cone beam computed tomography and detection of periodontal bone defects in patients with advanced periodontal disease indicated for periodontal surgeries. *Int J Head Neck Pathol* 2018;1:12-20.

## INTRODUCTION

Periodontal disease is characterized by periods of disease activity in which the supporting structures are destroyed by the action of chemical mediators generated by the inflammatory process followed by periods of relative inactivity or latency.<sup>[1,2]</sup> Radiographs play an important role in periodontal diagnosis; however, one of the major limitations of the conventional radiological procedures is the presence of considerable overlapping of the overlying anatomical structures and lack of a clear, three-dimensional information.<sup>[3-5]</sup> In a plethora of situations, this limitation of radiographs becomes an actual hindrance in the distinction between the buccal and palatal/lingual cortical aspects making it difficult to evaluate periodontal bone damage, especially in cases of crater defects and furcation involvements.<sup>[6-9]</sup> Although bitewing or interproximal radiography has yielded the best results in the evaluation of alveolar bone architecture including alveolar bone height, important features of the alveolar bone may go undetected as a result of the overlying structures or an unfavorable orientation of the central beam of the X-rays. Surgical exposure remains the only mean to ascertain precision of the defects or any other hidden pathology in such circumstances.<sup>[10]</sup> Surgical exposure, although being able to evaluate the type and depth of the defect during surgery, provides very little time to the surgeon to plan for the type of procedure required for periodontal regeneration based on the information obtained during surgery. Recently, cone beam computed tomography (CBCT) has emerged as a lower cost alternative to the computed tomography (CT) with high-quality images and lower radiation exposure to the patients.<sup>[11,12]</sup> For the detection of the smallest osseous defects, CBCT can display the image in all its three dimensions by removing the interfering anatomical structures making it possible to evaluate the given area of surgical interest extensively.<sup>[13-18]</sup> A number of studies have found CBCT to be as accurate as direct measurements made using a periodontal probe. Recent *in vitro* studies have, also, shown better precision in the evaluation of bone changes associated with periodontal disease using CBCT when compared to the conventional and digital radiographic procedures.<sup>[19,20]</sup> Unfortunately, *in vivo* studies, in this regard, are still scarce. The aim of the present study was to assess the efficacy of CBCT in the detection of periodontal bone defects in patients with advanced periodontal disease indicated for periodontal surgeries.

## MATERIALS AND METHODS

The present study was designed as a cross-sectional study wherein patients aged between 35 and 55 years

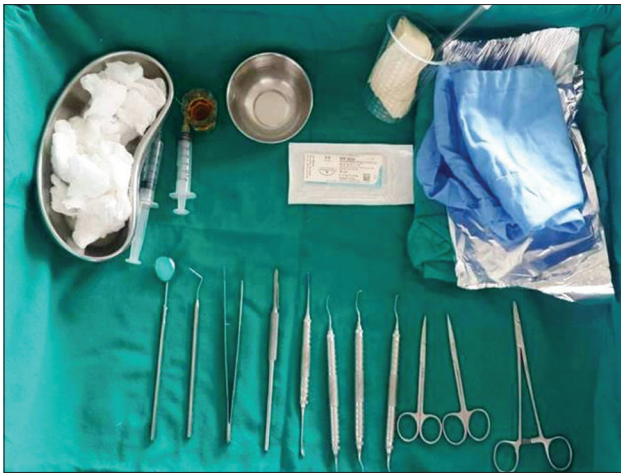with the advanced periodontal disease who were indicated for periodontal treatment in the form of periodontal surgeries were selected from the outpatient department. The exclusion criteria included subjects with systemic complications; pregnant and lactating females; subjects with a habit of smoking and/or tobacco chewing; patients with wasting diseases such as attrition, abrasion, erosion, and abfraction; and patients who had to undergo any restorative procedures in the areas of interest. Twelve patients with chronic periodontitis with 12 teeth each including six anterior and six posterior teeth were selected for making the measurements preoperatively and perioperatively. The sites selected for measurements included B-Buccal; BD-Buccal/Distal; BM-Buccal/Mesial; D-Distal; DB-Distal/Buccal; DP-Distal/Palatal or, Lingual in case of mandibular; M-Mesial; MB-Mesial/Buccal; MP-Mesial/Palatal or, Lingual; P-Palatal or, L-Lingual; PD-Palatal or, Lingual/Distal; and PM-Palatal or, Lingual/Mesial in case of maxillary and mandibular teeth, respectively. All patients who fulfilled the inclusion criteria and agreed to participate voluntarily with a written informed consent were considered for the study. The research protocol was approved by the Institutional Ethics Committee governing the use of human subjects in clinical research. A detailed case history was taken including chief complaint, history of presenting illness, and medical and personal histories. A thorough clinical examination, including systemic and regional examination, was done. All the patients were, then, subjected to the routine, conventional radiological procedures.

### Presurgical preparation

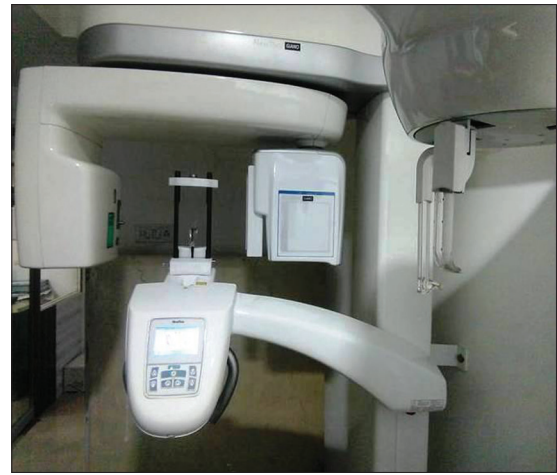Each patient received an initial periodontal treatment including oral hygiene instructions, plaque control, and full mouth scaling and root planing to achieve complete elimination of active inflammation [Figure 1]. Once the hygiene phase was completed and patients showed plaque proficiency up to mark, the surgical therapy was initiated.

### Radiographic assessment

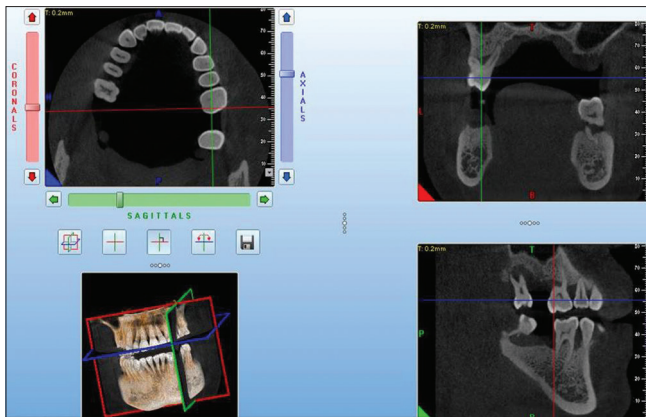
CBCT images were acquired for the same area of interest which was exposed for radiography during diagnosis and meeting of the study criteria. Images were acquired in a single 360° rotation around the head of the patient. The standard image-acquisition time was 36 s [Figure 2]. All the images were stored in Digital Imaging Communications in Medicine file format [Figures 3 and 4]. Following image acquisition, measurements were made using the proprietary NNT software (Version 5.4) integrated with NewTom GiANO equipment [Figures 5-8].



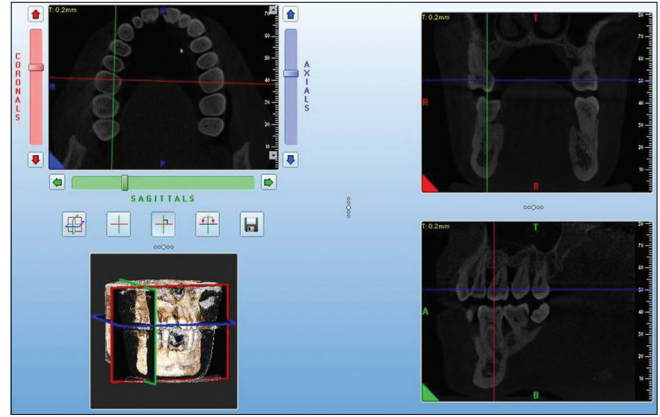
**Figure 1:** Armamentarium



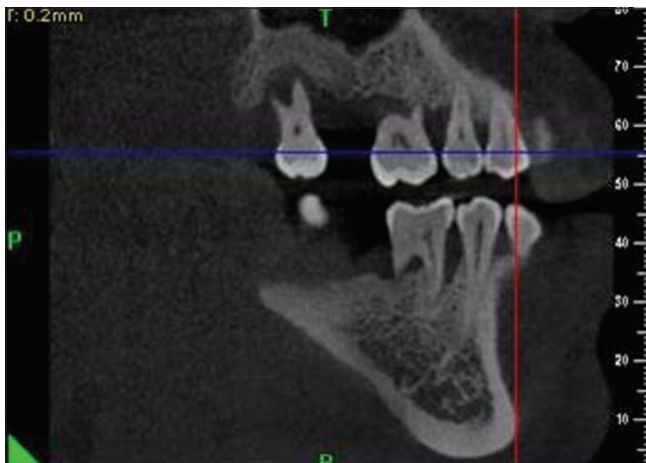
**Figure 2:** Cone beam computed tomography unit




**Figure 3:** Screenshot of cone beam computed tomography analysis (Case 1)



**Figure 4:** Screenshot of cone beam computed tomography analysis (Case 2)



**Figure 5:** Cone beam computed tomography view of bone defect (Case 1)



**Figure 6:** Measurement of defect with cone beam computed tomography software (Case 1)

### Surgical procedure

The patients were, then, subjected to the conventional open flap debridement procedure while measurements were obtained directly during the procedure.

### Assessment of depth of the bone defect

The depth of the bone defect was measured during the procedure in the same region where CBCT was taken. It was measured using the standard UNC-15 periodontal



probe to the nearest millimeter from the coronal extension of the alveolar bone crest to the deepest level of the defect [Figures 9 and 10].

### Postoperative care

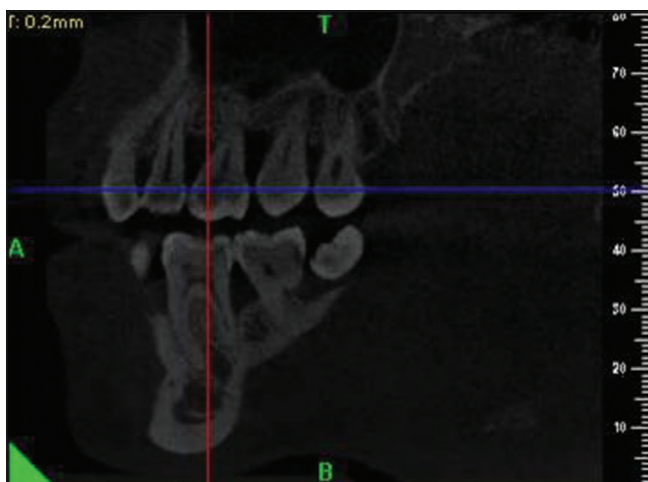
Antibiotic-anti-inflammatory coverage was prescribed for 5 days' postoperatively while all the patients were instructed to rinse with 0.2% chlorhexidine gluconate mouth rinse twice daily until 4 weeks. Periodontal dressing and sutures were removed 7 days' postoperatively. After 1 month, the patients were instructed to resume mechanical oral hygiene measures including careful brushing with an ultrasoft toothbrush and interdental cleaning with an interdental or, proxabrush and to discontinue chlorhexidine gluconate mouth rinse. Subgingival scaling and probing were avoided for first 6 months to allow the newly forming connective tissue to mature while the patients who had received the regenerative therapy were recalled after 6 months for further evaluation and needful.

### Statistical analysis

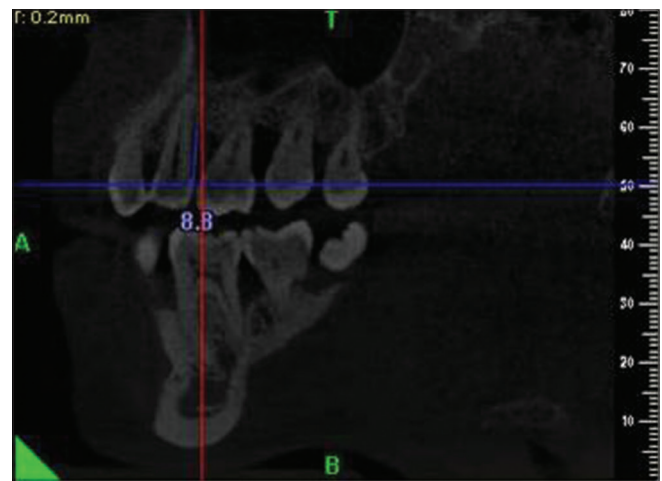
Statistical analysis was done using SPSS version 18.0 (SPSS Inc., Chicago, IL, USA). Both the measurements were compared in each anterior and posterior tooth with the help of Student's *t*-test. If  $P > 0.05$ , the difference observed was considered statistically insignificant while if  $\leq 0.05$  ( $P < 0.05$ ), it was considered statistically significant. Pearson's coefficient correlation test was, also, used to test the correlation between the observed values while unpaired *t*-test was used to compare the data in the same measurement method used.

### RESULTS

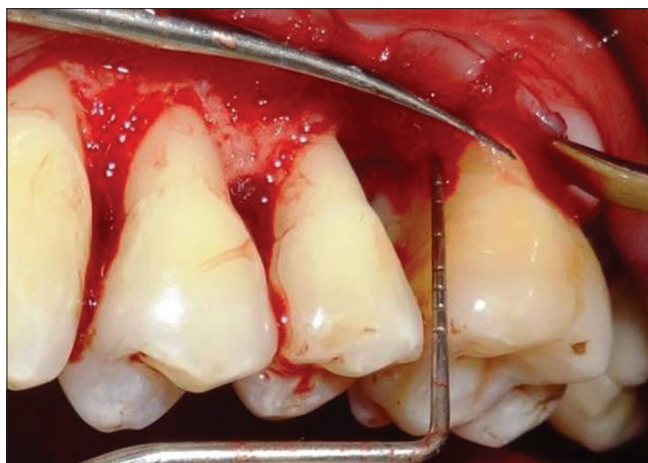Twelve patients including six males and six females with a mean age of 35.5 years with advanced periodontal disease indicated for periodontal surgeries were included in the study. The palatal/lingual sites in anterior teeth which showed a mean CBCT value of 4.0444 mm and mean



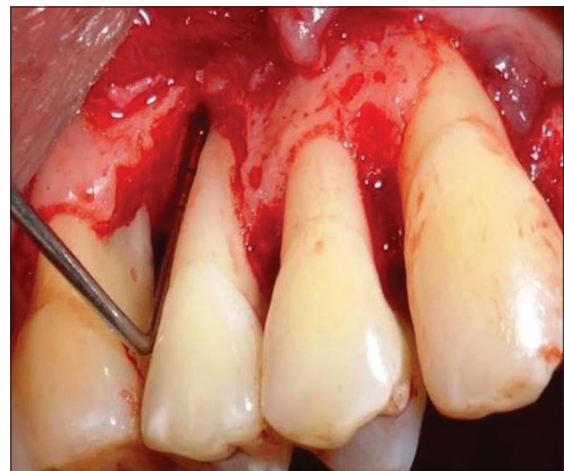**Figure 7:** Cone beam computed tomography view of bone defect (Case 2)



**Figure 8:** Measurement of defect with cone beam computed tomography software (Case 2)



**Figure 9:** Defect exposed after debridement (Case 1)



**Figure 10:** Defect exposed after debridement (Case 2)

surgical value of 4.1822 mm revealed the mean difference to be statistically significant along with the distal sites which showed a mean CBCT value of 3.3667 mm and mean surgical value of 3.5217 mm ( $P = 0.001$ ) [Table 1]. The values, though, in case of posterior teeth were not found to be statistically significant [Table 2]. Furthermore, the Pearson's correlation coefficient test for various sites in the anterior and posterior teeth was found to be highly significant in all the cases ( $P = 0.001$ ) [Tables 3 and 4]. The present study, however, revealed that within the same analytical parameters, when unpaired *t*-test was applied, it was found that there was a significant difference between the mesial and distal sites in posterior teeth in the measurements made during the surgical intervention ( $P = 0.043$ ) [Table 5].

### DISCUSSION

CBCT has opened up a new vista in maxillofacial imaging facilitating the transition of diagnostics from two-dimensional to three-dimensional imaging and having the potential to expand the role of dental imaging from mere diagnosis to image-guided operative procedures and surgeries. Numerous studies have validated the use of CBCT in the planning of implant cases, in the study of temporomandibular diseases, in the diagnosis of embedded teeth, in orthodontics and dentofacial orthopedics, and in numerous other pathologies,<sup>[19,21-38]</sup> however, few have analyzed the need for CBCT in periodontal diagnosis and treatment planning. Recently, a few *in vivo* studies have been published concerning periodontal bone defect measurements using CBCT; however, only a few of these actually relate the accuracy of CBCT in the assessment of horizontal in addition to the vertical bone defects which form the mainstay of these studies.<sup>[7,8,15,36,39-42]</sup> The main advantages of CBCT include good accessibility and easy handling in addition to a real-size dataset with multiplanar cross-sectional images and three-dimensional image reconstructions based on a single scan at low-radiation exposure with optimal image quality, the advantages which have actually made CBCT even more promising than CT.<sup>[43,44]</sup> Although Vandenberghe *et al.*<sup>[19]</sup> suggested CBCT to be used only for relatively complex periodontal treatment planning and potential use of dental implants, this imaging modality may provide a new tool for periodontal imaging, especially in cases wherein an interdisciplinary approach to treatment planning is necessary.

The aim of the present study was to assess the efficacy of CBCT in the detection of periodontal bone defects in patients with advanced periodontal disease indicated for periodontal surgeries wherein the palatal/lingual sites in anterior teeth

**Table 1: Comparison of measurements from various sites in the anterior teeth by paired *t*-test**

Site (Anterior)	Method	Mean	Std.dev.	Std. error	<i>t</i>	<i>p</i>
Buccal	Surgical	4.1950	1.84685	0.13766	1.375	0.171
	CBCT	4.1556	1.92259	0.14330		
Palatal/Lingual	Surgical	4.1822	1.93478	0.14421	3.504	0.001**
	CBCT	4.0444	1.98830	0.14820		
Mesial	Surgical	4.1982	2.10964	0.27235	0.287	0.775
	CBCT	4.1547	2.12341	0.27413		
Distal	Surgical	3.5217	1.31717	0.17005	3.524	0.001**
	CBCT	3.3667	1.35255	0.17461		

\*\* $P < 0.001$ - Highly significant

**Table 2: Comparison of measurements from various sites in the posterior teeth by paired *t*-test**

Site (posterior)	Method	Mean	SD	SE	<i>t</i>	<i>P</i>
Buccal	Surgical	5.9833	1.83288	0.13657	-1.444	0.150
	CBCT	6.0656	1.78652	0.13316		
Palatal/lingual	Surgical	6.1556	1.72986	0.12894	0.835	0.405
	CBCT	6.1111	1.73932	0.12964		
Mesial	Surgical	5.6444	1.63284	0.12170	-1.310	0.192
	CBCT	5.6956	1.5774	0.11757		
Distal	Surgical	6.0389	2.02874	0.15121	0.897	0.731
	CBCT	6.0867	1.97734	0.14738		

CBCT: Cone beam computed tomography, SD: Standard deviation, SE: Standard error

**Table 3: Pearson's correlation coefficient test for various sites in the anterior teeth**

Site (Anterior)	Method	Correlation	<i>p</i>
Buccal	Surgical	0.980	<0.001**
	CBCT		
Palatal/Lingual	Surgical	0.964	<0.001**
	CBCT		
Mesial	Surgical	0.956	<0.001**
	CBCT		
Distal	Surgical	0.968	<0.001**
	CBCT		

\*\* $P < 0.001$ - Highly significant

**Table 4: Pearson's correlation coefficient test for various sites in the posterior teeth**

Site (Posterior)	Method	Correlation	<i>p</i>
Buccal	Surgical	0.911	<0.001**
	CBCT		
Palatal/Lingual	Surgical	0.915	<0.001**
	CBCT		
Mesial	Surgical	0.947	<0.001**
	CBCT		
Distal	Surgical	0.937	<0.001**
	CBCT		

\*\* $P < 0.001$ - Highly Significant

which showed a mean CBCT value of 4.0444 mm and mean surgical value of 4.1822 mm revealed the mean difference to be statistically significant along with the distal sites which showed a mean CBCT value of 3.3667 mm and mean surgical value of 3.5217 mm ( $P = 0.001$ ). The said results were found to be in agreement with the results obtained in the study conducted by Mol and Balasundaram<sup>[40]</sup> who found CBCT to be associated with lesser accuracy in the

**Table 5: Unpaired t-test for the surgical and CBCT measurements in anterior as well as posterior teeth**

Method	Site	t	p
Surgical (Posterior)	Mesial	2.302	0.043*
	Distal		
CBCT (Posterior)	Mesial	1.789	0.075
	Distal		
Surgical (Posterior)	Buccal	-0.917	0.360
	Palatal		
CBCT (Posterior)	Buccal	-0.245	0.806
	Palatal		
Surgical (Anterior)	Buccal	0.767	0.444
	Palatal		
CBCT (Anterior)	Buccal	0.764	0.446
	Palatal		
Surgical (Anterior)	Mesial	0.355	0.723
	Distal		
CBCT (Anterior)	Mesial	0.128	0.829
	Distal		

\*P&lt;0.05- Statistically significant

measurement of buccal bone defects in the anterior region of mandible in comparison with the posterior region on images with the New Tom 9000 scanner. The reason behind such findings was attributed to the thinner buccal and lingual cortical plates in the anterior teeth than that is present in the posterior teeth. Fuhrmann *et al.*<sup>[8]</sup> also, found that bone defects with wall thickness <0.2 mm were not apparent on tomographic imaging using helical CT. Till date, none of the studies have indicated the least bone wall thickness that can be identified on CBCT imaging. The present study, therefore, highlights the need for such comparative studies for assessing the minimum bone wall thickness that can be identified accurately on CBCT imaging. Furthermore, the values in case of posterior teeth, though, more accurate than the anterior teeth, were not found to be statistically significant in the present study. This, too, was found to be in agreement with the findings of the studies conducted by de Faria Vasconcelos *et al.*,<sup>[7]</sup> Grimard *et al.*,<sup>[10]</sup> and Feijo *et al.*<sup>[18]</sup> with the variations found in the accuracy of CBCT in anterior and posterior teeth imaging being likely the result of the difference in the morphology of the periodontal bone defects in each region. The lingual plates are considerably thinner in the anterior region, and the bone tapers toward the alveolar crest in case of the anterior teeth than in teeth in the posterior regions. A thinner bone plate has low-image resolution decreasing the precision of the linear measurements made in case of anterior teeth. This limitation of CT/CBCT in such cases might be due to the property denominated as partial volume averaging wherein when the limit between two tissues is in the middle of a voxel; its density is not accurately assessed by the said imaging modality, be it CT and/or CBCT.<sup>[43,44]</sup> Apparently, the quality of the image slices, in such cases, is insufficient to resolve the alveolar crest reliably in the said regions resulting in lesser diagnostic accuracy.

In addition, although CBCT appears to be a promising option for periodontal imaging, the image quality actually achievable with CBCT essentially depends on the actual dose applied during CBCT, despite the variations in the actual dose and the image quality achieved, CBCT, still, proves to be a dose-sparing technique compared to the alternative medical/conventional CT as was found in the study conducted by Ludlow *et al.*<sup>[45]</sup> comparing the impact of two different effective doses for obtaining optimal quality images. A review of the recent studies on the said image modalities, also, positively affirms CBCT to be superior to the conventional radiological and imaging modalities.<sup>[46]</sup> However, since there is a relative dearth of studies in this regard with not much work done in relating the efficacy of CBCT as against the conventional radiography and CT,<sup>[47,48]</sup> further *in vitro* and *in vivo* research is highly mandated to optimize the basic radiation dose required for obtaining optimal quality images without compromising the required diagnostic detailing. Furthermore, the spatial resolution of CBCT is dependent on the voxel dimensions used during scanning wherein a plethora of studies has investigated the influence of voxel dimensions on the imaging outcomes in different clinical settings.<sup>[49,50]</sup> Smaller voxel dimensions have been hypothesized to result in greater resolution of the images; however, higher radiation doses are needed in such clinical settings. Wood *et al.*,<sup>[51]</sup> however, when conducted a study to determine the factors affecting the alveolar bone height measurements from CBCT images, had contradictory findings and concluded that the voxel-dimension factor had an insignificant impact on the alveolar bone height measurements in CBCT imaging. Several other factors cited in this regard of significance include the quantity and quality of the bone being imaged, the skill of the examiner, the software used to view and analyze the CBCT images and the presence or absence of soft-tissue at and in and around the site of interest might.<sup>[52-57]</sup> In the present study, a voxel size of 0.2 mm was used as against 0.4 mm used in the *in vitro* study conducted by Vandenberghe *et al.*<sup>[19]</sup> to obtain higher-resolution images as the present study was an *in vivo* study. Although radiation dose used in the present study was well below the conservative limits recommended by the National Council on Radiation Protection and Measurements even at the highest CBCT exposure settings, further studies are mandated to determine the ideal exposure settings that could optimize the image quality.

Misch *et al.*<sup>[6]</sup> hypothesized CBCT analysis to be as accurate as direct measurements made using the standard UNC-15 periodontal probing. The present study, however, revealed that within the same analytical parameters, when unpaired t-test was applied, it was found that there was a significant



difference between the mesial and distal sites in case of posterior teeth in the measurements made during the surgical intervention ( $P = 0.043$ ). This difference could be explained by the fact that the distal site accessibility is difficult while performing periodontal surgeries and taking such measurements, especially, in case of molars. CBCT, on the contrary, in such situations, provided good accessibility to visualize the sites which were otherwise difficult to access during surgical intervention including the distal sites of the posterior teeth. The findings of the present study were, also, found to be in agreement with the results of the study conducted by Feijo *et al.*<sup>[18]</sup> who concluded that clinical measurements obtained using the standard UNC-15 periodontal probe were found to be with an accuracy of up to 1 mm whereas CBCT measurements allowed an accuracy of up to three decimal places. In an ideal setting, a discrepancy of 0.5 mm between the clinically and radiographically estimated bone levels is considered to be acceptable. Smaller or larger errors in locating the cemento-enamel junction and alveolar crestal levels can respectively lead to over- and under-estimation of the disease progression in the said situations.

Furthermore, due to the limitations of using re-entry surgeries to evaluate grafting outcomes, radiographic techniques such as intraoral radiology, digital subtraction radiography, and computer-assisted densitometric image analysis have been used as alternative methods for assessment of grafting outcomes in such situations,<sup>[58]</sup> although all three of the said radiographic techniques are difficult to be standardized from two different surgery time points. Furthermore, the primary limitation of all these radiographic techniques is the reliability of two-dimensional imaging to assess three-dimensional morphologic changes. CBCT might be prove to be a useful and more precise clinical tool for the assessment of periodontal surgical outcomes over varying time scales in such clinical settings. Data from CBCT can be helpful in the preoperative evaluation of the bone topography and architecture of the bone defect as well as in the optimization of the surgical treatment planning and treatment outcomes in such situations.

From the literature so far, CBCT can be said to help diagnose more accurately the periodontal disease and its varied aspects such as the amount of bone loss, its extent, type of defect existing, its dimensions and extent of the involvement of furcations in case of posterior teeth and to determine precisely the prognosis of each tooth by allowing a three-dimensional analysis of the surrounding bone. To conclude, CBCT provides better evaluation of the bone topography preoperatively which gives precision in the

assessment of the type and depth of the defect present and helps optimizing the surgical treatment planning and treatment outcomes, however, further clinical studies are, still, necessary to establish the selection criteria that define conditions and specific indications for the use of this imaging modality in periodontal diagnosis and treatment planning keeping radiation exposure to the minimal with optimal diagnostic accuracy and with all these aspects, eventually, contributing to significantly improve the quality of periodontal care provided.

## CONCLUSION

From the observations made from the present study, it could be concluded that CBCT provided good accessibility to visualize sites which were otherwise difficult to access during surgery. In addition, the bone density/volume could be detected precisely with the CBCT software which was otherwise not possible with the conventional methods. The diagnostic accuracy of CBCT, though, was found to be lesser for anterior than for the posterior teeth in accordance with the findings reported in numerous other studies in the literature, too, however, till date, none of the studies have indicated the least bone wall thickness that can be identified on CBCT imaging. The present study, therefore, highlights the need for such comparative studies in the future assessing the minimum bone wall thickness that can be identified accurately on CBCT imaging.

## Future research directions

Although CBCT appears to be a promising impending option for periodontal imaging, the image quality actually achievable with CBCT essentially depends on the actual dose applied during CBCT. However, since there is a relative dearth of studies in this regard with not much work done in relating the efficacy of CBCT as against the conventional radiography and CT, further *in vitro* and *in vivo* research is highly mandated to optimize the basic radiation dose required for obtaining optimal quality images without compromising the required diagnostic detailing. Furthermore, the spatial resolution of CBCT has been hypothesized to be dependent on the voxel dimensions used during scanning and smaller voxel dimensions, though, said to result in greater resolution of the images, have been associated with higher radiation doses. This area, too, has been largely unexplored in the studies conducted so far and mandates further studies to be conducted to determine the ideal exposure settings that could optimize the image quality and required diagnostic detailing.

## Financial support and sponsorship

Nil.

## Conflicts of interest

There are no conflicts of interest.

## REFERENCES

- Newman M, Takei HH, Carranza FA. Clinical periodontology. In: Carranza FA, Takei HH, editors. Radiographic Aids in the Diagnosis of Periodontal Disease. Philadelphia: W.B. Saunders Company; 2002. p. 454-68.
- Highfield J. Diagnosis and classification of periodontal disease. Aust Dent J 2009;54 Suppl 1:S11-26.
- Pepelessi EA, Diamanti-Kipiotti A. Selection of the most accurate method of conventional radiography for the assessment of periodontal osseous destruction. J Clin Periodontol 1997;24:557-67.
- Cotti E, Campisi G. Advanced radiographic techniques for the detection of lesions in bone. Endod Topics 2004;7:52-72.
- Mol A. Imaging methods in periodontology. Periodontol 2000 2004;34:34-48.
- Eickholz P, Hausmann E. Accuracy of radiographic assessment of interproximal bone loss in intrabony defects using linear measurements. Eur J Oral Sci 2000;108:70-3.
- de Faria Vasconcelos K, Evangelista KM, Rodrigues CD, Estrela C, de Sousa TO, Silva MA, *et al.* Detection of periodontal bone loss using cone beam CT and intraoral radiography. Dentomaxillofac Radiol 2012;41:64-9.
- Fuhrmann RA, Buecker A, Diedrich PR. Furcation involvement: Comparison of dental radiographs and HR-CT-slices in human specimens. J Periodontol Res 1997;32:409-18.
- Eskandarloo A, Bardal R, Dehghani M. Accuracy of cone beam computed tomography, intraoral radiography and periodontal probing for periodontal bone defects measurement. J Dent Med Tehran Univ Med Sci 2011;24:15-9.
- Grimard BA, Hoidal MJ, Mills MP, Mellonig JT, Nummikoski PV, Mealey BL, *et al.* Comparison of clinical, periapical radiograph, and cone-beam volume tomography measurement techniques for assessing bone level changes following regenerative periodontal therapy. J Periodontol 2009;80:48-55.
- Scarfe WC, Farman AG, Sukovic P. Clinical applications of cone-beam computed tomography in dental practice. J Can Dent Assoc 2006;72:75-80.
- Hounsfield GN. Computerized transverse axial scanning (tomography). 1. Description of system. Br J Radiol 1973;46:1016-22.
- Banodkar AB, Gaikwad RP, Gunjekar TU, Lobo TA. Evaluation of accuracy of cone beam computed tomography for measurement of periodontal defects: A clinical study. J Indian Soc Periodontol 2015;19:285-9.
- Mohan R, Singh A, Gundappa M. Three-dimensional imaging in periodontal diagnosis – Utilization of cone beam computed tomography. J Indian Soc Periodontol 2011;15:11-7.
- Leung CC, Palomo L, Griffith R, Hans MG. Accuracy and reliability of cone-beam computed tomography for measuring alveolar bone height and detecting bony dehiscences and fenestrations. Am J Orthod Dentofacial Orthop 2010;137:S109-19.
- Misch KA, Yi ES, Sarment DP. Accuracy of cone beam computed tomography for periodontal defect measurements. J Periodontol 2006;77:1261-6.
- Pinsky HM, Dyda S, Pinsky RW, Misch KA, Sarment DP. Accuracy of three-dimensional measurements using cone-beam CT. Dentomaxillofac Radiol 2006;35:410-6.
- Feijo CV, Lucena JG, Kurita LM, Pereira SL. Evaluation of cone beam computed tomography in the detection of horizontal periodontal bone defects: An *in vivo* study. Int J Periodontics Restorative Dent 2012;32:e162-8.
- Vandenbergh B, Jacobs R, Yang J. Diagnostic validity (or acuity) of 2D CCD versus 3D CBCT-images for assessing periodontal breakdown. Oral Surg Oral Med Oral Pathol Oral Radiol Endod 2007;104:395-401.
- du Bois AH, Kardachi B, Bartold PM. Is there a role for the use of volumetric cone beam computed tomography in periodontics? Aust Dent J 2012;57 Suppl 1:103-8.
- Mischkowski RA, Pulsfort R, Ritter L, Neugebauer J, Brochhagen HG, Keeve E, *et al.* Geometric accuracy of a newly developed cone-beam device for maxillofacial imaging. Oral Surg Oral Med Oral Pathol Oral Radiol Endod 2007;104:551-9.
- Tyndall DA, Rathore S. Cone-beam CT diagnostic applications: Caries, periodontal bone assessment, and endodontic applications. Dent Clin North Am 2008;52:825-41, vii.
- Veyre-Goulet S, Fortin T, Thierry A. Accuracy of linear measurement provided by cone beam computed tomography to assess bone quantity in the posterior maxilla: A human cadaver study. Clin Implant Dent Relat Res 2008;10:226-30.
- Januário AL, Barriviera M, Duarte WR. Soft tissue cone-beam computed tomography: A novel method for the measurement of gingival tissue and the dimensions of the dentogingival unit. J Esthet Restor Dent 2008;20:366-73.
- Barriviera M, Duarte WR, Januário AL, Faber J, Bezerra AC. A new method to assess and measure palatal masticatory mucosa by cone-beam computerized tomography. J Clin Periodontol 2009;36:564-8.
- Van Assche N, van Steenberghe D, Quirynen M, Jacobs R. Accuracy assessment of computer-assisted flapless implant placement in partial edentulism. J Clin Periodontol 2010;37:398-403.
- Chen LC, Lundgren T, Hallström H, Chere F. Comparison of different methods of assessing alveolar ridge dimensions prior to dental implant placement. J Periodontol 2008;79:401-5.
- Suomalainen A, Vehmas T, Kortensniemi M, Robinson S, Peltola J. Accuracy of linear measurements using dental cone beam and conventional multislice computed tomography. Dentomaxillofac Radiol 2008;37:10-7.
- Al-Ekrish AA, Ekram M. A comparative study of the accuracy and reliability of multidetector computed tomography and cone beam computed tomography in the assessment of dental implant site dimensions. Dentomaxillofac Radiol 2011;40:67-75.
- Kobayashi K, Shimoda S, Nakagawa Y, Yamamoto A. Accuracy in measurement of distance using limited cone-beam computerized tomography. Int J Oral Maxillofac Implants 2004;19:228-31.
- Kamburoğlu K, Kiliç C, Ozen T, Yüksel SP. Measurements of mandibular canal region obtained by cone-beam computed tomography: A cadaveric study. Oral Surg Oral Med Oral Pathol Oral Radiol Endod 2009;107:e34-42.
- Berco M, Rigali PH Jr., Miner RM, DeLuca S, Anderson NK, Will LA, *et al.* Accuracy and reliability of linear cephalometric measurements from cone-beam computed tomography scans of a dry human skull. Am J Orthod Dentofacial Orthop 2009;136:17.e1-9.
- Periago DR, Scarfe WC, Moshiri M, Scheetz JP, Silveira AM, Farman AG, *et al.* Linear accuracy and reliability of cone beam CT derived 3-dimensional images constructed using an orthodontic volumetric rendering program. Angle Orthod 2008;78:387-95.
- Brown AA, Scarfe WC, Scheetz JP, Silveira AM, Farman AG. Linear accuracy of cone beam CT derived 3D images. Angle Orthod 2009;79:150-7.
- Lagravère MO, Carey J, Toogood RW, Major PW. Three-dimensional accuracy of measurements made with software on cone-beam computed tomography images. Am J Orthod Dentofacial Orthop 2008;134:112-6.
- Loubele M, Van Assche N, Carpentier K, Maes F, Jacobs R, van Steenberghe D, *et al.* Comparative localized linear accuracy of small-field cone-beam CT and multislice CT for alveolar bone measurements. Oral Surg Oral Med Oral Pathol Oral Radiol Endod 2008;105:512-8.
- Sakabe J, Kuroki Y, Fujimaki S, Nakajima I, Honda K. Reproducibility and accuracy of measuring unerupted teeth using limited cone beam X-ray CT. Dentomaxillofac Radiol 2007;36:2-6.



Nayyar: Cone beam computed tomography and detection of periodontal bone defects in advanced periodontal disease

38. Moreira CR, Sales MA, Lopes PM, Cavalcanti MG. Assessment of linear and angular measurements on three-dimensional cone-beam computed tomographic images. *Oral Surg Oral Med Oral Pathol Oral Radiol Endod* 2009;108:430-6.
39. Eshraghi T, McAllister N, McAllister B. Clinical applications of digital 2-D and 3-D radiography for the periodontist. *J Evid Based Dent Pract* 2012;12:36-45.
40. Mol A, Balasundaram A. *In vitro* cone beam computed tomography imaging of periodontal bone. *Dentomaxillofac Radiol* 2008;37:319-24.
41. Noujeim M, Prihoda T, Langlais R, Nummikoski P. Evaluation of high-resolution cone beam computed tomography in the detection of simulated interradicular bone lesions. *Dentomaxillofac Radiol* 2009;38:156-62.
42. Walter C, Weiger R, Zitzmann NU. Accuracy of three-dimensional imaging in assessing maxillary molar furcation involvement. *J Clin Periodontol* 2010;37:436-41.
43. Scarfe WC, Farman AG, Levin MD, Gane D. Essentials of maxillofacial cone beam computed tomography. *Alpha Omegan* 2010;103:62-7.
44. Kamburoğlu K, Acar B, Yakar EN, Paksoy CS. Dento-maxillofacial cone beam computerized tomography part 1: Basic principles. *J Clin Sci* 2012;6:1125-36.
45. Ludlow JB, Davies-Ludlow LE, Brooks SL. Dosimetry of two extraoral direct digital imaging devices: NewTom cone beam CT and orthophos plus DS panoramic unit. *Dentomaxillofac Radiol* 2003;32:229-34.
46. Hanazawa T, Sano T, Seki K, Okano T. Radiologic measurements of the mandible: A comparison between CT-reformatted and conventional tomographic images. *Clin Oral Implants Res* 2004;15:226-32.
47. Fuhrmann RA, Bücker A, Diedrich PR. Assessment of alveolar bone loss with high resolution computed tomography. *J Periodontol* 1995;30:258-63.
48. Van Dessel J, Huang Y, Depypere M, Rubira-Bullen I, Maes F, Jacobs R, *et al*. A comparative evaluation of cone beam CT and micro-CT on trabecular bone structures in the human mandible. *Dentomaxillofac Radiol* 2013;42:20130145.
49. Hekmatian E, Jafari-Pozve N, Khorrani L. The effect of voxel size on the measurement of mandibular thickness in cone-beam computed tomography. *Dent Res J (Isfahan)* 2014;11:544-8.
50. de-Azevedo-Vaz SL, Vasconcelos Kde F, Neves FS, Melo SL, Campos PS, Haiter-Neto F, *et al*. Detection of periimplant fenestration and dehiscence with the use of two scan modes and the smallest voxel sizes of a cone-beam computed tomography device. *Oral Surg Oral Med Oral Pathol Oral Radiol* 2013;115:121-7.
51. Wood R, Sun Z, Chaudhry J, Tee BC, Kim DG, Leblebicioglu B, *et al*. Factors affecting the accuracy of buccal alveolar bone height measurements from cone-beam computed tomography images. *Am J Orthod Dentofacial Orthop* 2013;143:353-63.
52. Lascala CA, Panella J, Marques MM. Analysis of the accuracy of linear measurements obtained by cone beam computed tomography (CBCT-newTom). *Dentomaxillofac Radiol* 2004;33:291-4.
53. Tomasi C, Bressan E, Corazza B, Mazzoleni S, Stellini E, Lith A, *et al*. Reliability and reproducibility of linear mandible measurements with the use of a cone-beam computed tomography and two object inclinations. *Dentomaxillofac Radiol* 2011;40:244-50.
54. Braun X, Ritter L, Jervøe-Storm PM, Frentzen M. Diagnostic accuracy of CBCT for periodontal lesions. *Clin Oral Investig* 2014;18:1229-36.
55. Marmulla R, Wörtche R, Mühling J, Hassfeld S. Geometric accuracy of the NewTom 9000 cone beam CT. *Dentomaxillofac Radiol* 2005;34:28-31.
56. Stratemann SA, Huang JC, Maki K, Miller AJ, Hatcher DC. Comparison of cone beam computed tomography imaging with physical measures. *Dentomaxillofac Radiol* 2008;37:80-93.
57. Sun Z, Smith T, Kortam S, Kim DG, Tee BC, Fields H, *et al*. Effect of bone thickness on alveolar bone-height measurements from cone-beam computed tomography images. *Am J Orthod Dentofacial Orthop* 2011;139:e117-27.
58. Langer B, Gelb DA, Krutchkoff DJ. Early re-entry procedure. Part II. A five year histologic evaluation. *J Periodontol* 1981;52:135-9.