

# Diagnostic issue and caveats of immunoreactivity for Ki67 in hyalinizing trabecular neoplasm with review of literature: A study of one case

Veer Karuna, Priya Gupta, Mamta Gupta<sup>1</sup>, Kriti Grover

Department of Pathology, L.L.R.M. Medical College, <sup>1</sup>Department of Pathology, Subharti Medical College, Meerut, Uttar Pradesh, India

**Abstract** Few benign and malignant thyroid lesions share many histological features including papillary and trabecular pattern, hyalinized stroma, calcification, nuclear grooving and nuclear inclusion. Well formalin fixed right lobe hemithyroidectomy specimen was received. After processing, H and E stain was done. Immunohistochemical studies (TTF, Thyroglobuline, MIB-1) and special stain (Congo red) were done to make a definite diagnosis. The present case describes a relatively rare thyroid tumour – Hyalinizing trabecular tumour with its varied morphological features creating diagnostic difficulties and role of IHC in formulating definitive diagnosis.

**Keywords:** Hyalinizing trabecular tumor, Ki67 (clone MIB-1 and SP6), papillary thyroid carcinoma

**Address for correspondence:** Dr. Veer Karuna, Department of Pathology, L.L.R.M. Medical College, Meerut, Uttar Pradesh, India.  
E-mail: [dr.veera02@gmail.com](mailto:dr.veera02@gmail.com)

## INTRODUCTION

Hyalinizing Trabecular Tumor (HTT) was first described by Carney and colleagues in 1987. The term hyalinized trabecular adenoma was replaced by tumour due to its features consisting of large trabeculae with intratrabecular and intertrabecular hyaline material.<sup>[1]</sup> The majority of these cases have a benign course, but according to 2017 WHO Classification of Thyroid Tumors described this tumor as borderline/precursor tumors.<sup>[2]</sup> In the largest series of cases the tumor was noted more common in the right lobe of the thyroid. Prevalent in females between the fourth and fifth decades of age, was originally defined as infrequent but potentially a confusing neoplasm.<sup>[3]</sup>

## CASE REPORT

A 35 years old Indian male patient complained of midline neck swelling of two months duration. Physical

examination revealed a mass in the right lobe of thyroid measuring 3 × 3 cm in size. There was no significant family or previous history of surgery or radiation exposure. Serum thyroid profile assay were within normal limits. MRI showed an enlarged right lobe of thyroid gland with well-defined oval lobulated lesion measuring 5.2 × 4.8 × 3.8 cm in size, suggesting possibility of thyroid adenoma [Figure 1a]. FNAC was performed; however, findings were nonspecific with only few clusters of benign follicular epithelial cells. Patient underwent right hemithyroidectomy. The extirpated tumor was 5 × 4 × 3 cm in size showed clear margins. It was circumscribed but not encapsulated [Figure 1b]. The parenchymal tumor cells were homogenous and arranged in trabecular pattern and nests separated by hyalinized stroma. The tumor cells were elongated to ovoid with round nucleus, focal nuclear grooving and

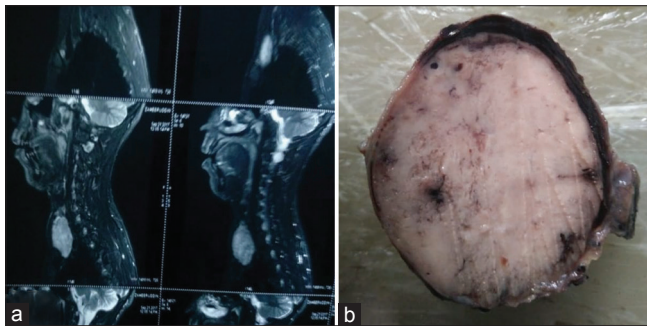
This is an open access journal, and articles are distributed under the terms of the Creative Commons Attribution-NonCommercial-ShareAlike 4.0 License, which allows others to remix, tweak, and build upon the work non-commercially, as long as appropriate credit is given and the new creations are licensed under the identical terms.

**For reprints contact:** [reprints@medknow.com](mailto:reprints@medknow.com)

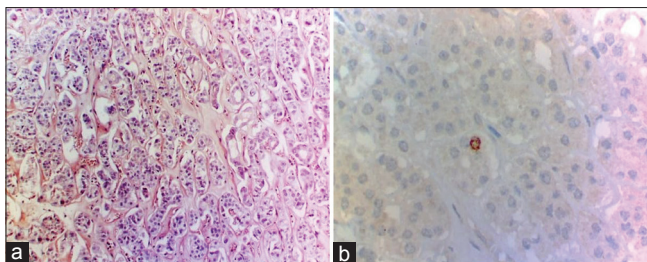
**How to cite this article:** Karuna V, Gupta P, Gupta M, Grover K. Diagnostic issue and caveats of immunoreactivity for Ki67 in hyalinizing trabecular neoplasm with review of literature: A study of one case. *Int J Head Neck Pathol* 2018;1:1-4.

Access this article online	
Quick Response Code:	Website: <a href="http://www.ijhnp.org">www.ijhnp.org</a>
	DOI: 10.4103/JHNP.JHNP_6_18

moderate amphophilic cytoplasm [Figure 2]. Occasional trabeculae had round to irregularly shaped follicles that were either empty or contained colloid. No mitotic figures were detected. The margins were sharp, revealing no invasion of the surrounding tissues with no capsular and vascular invasion. Granular calcific material was present. A diagnosis of Hyalinizing trabecular tumor (HTT) was considered. However, due to overlapping features with other thyroid neoplasm like papillary thyroid carcinoma (PTC), medullary thyroid carcinoma (MTC), Trabecular follicular adenoma (TFA), poorly differentiated tumor (PDT) and Paraganglioma. Histochemistry with Congo red stain was done revealing absence of apple green birefringence on polarized microscopy, thereby excluding possibility of medullary carcinoma [Figure 3a]. Immunohistochemistry for TTF, thyroglobulin and Ki67 Clone MIB1 (Dako) was performed using polymer labeling technique on automated immunostainer, while Ki67 Clone SP6 (cell marque) was done in semiautomated antigen retrieval system. Immunohistochemistry for Ki67 using both MIB-1 and SP6 clone showed nuclear positivity in <1% of follicular cells, thereby differentiating from other thyroid malignancies [Figure 3b]. TTF showed nuclear positivity with moderate intensity and Thyroglobulin was strongly positive, the latter two help in differentiating from Paraganglioma [Figure 4].



**Figure 1:** (a) Showed an enlarged right lobe of thyroid gland with well-defined oval lobulated lesion measuring 3.8 cm × 4.8 cm × 5.2 cm in size, (b) Gross photograph showing well circumscribed globular mass of 5 cm × 4 cm × 3 cm in size. The cut surface was homogeneously pale and firm with focal hemorrhagic areas

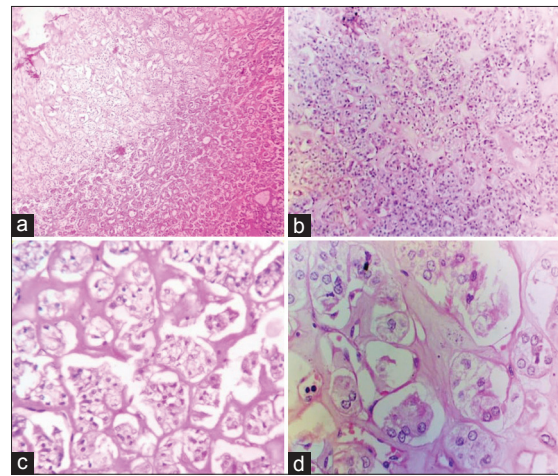


**Figure 3:** (a) The hyaline material of the tumor is Congo red negative (×100), (b) IHC Ki-67 stain - focal nuclear positivity (×400)

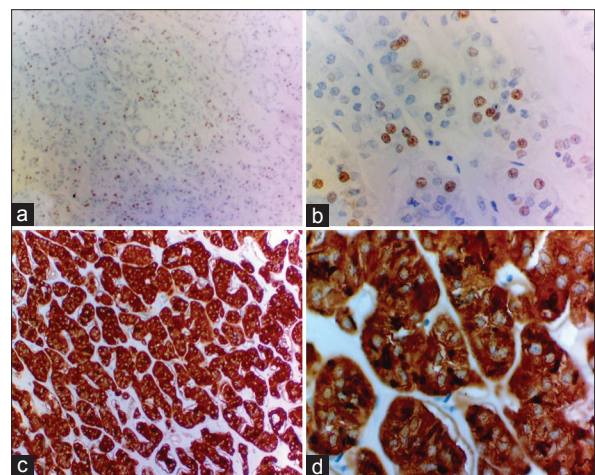
## DISCUSSION

We are presenting a case report that share few but common architectural features including trabecular growth pattern, nuclear grooving, hyalinized material and focal granular calcification. The differential diagnoses considered with these features were HTT, PTC, MC, Paraganglioma, TFA and PDT.

HTT and TFA are conceivably rare type of follicular cell neoplasm and frequently misinterpreted as PTC, MC and Paraganglioma due to some common histological features. The diagnosis of HTT is challenging due to many controversial aspects in regards to its diagnosis, classification, differential diagnosis and malignant potential.<sup>[3,4]</sup> HTT



**Figure 2:** (a and b) Showing abrupt onset of tumor with Prominent trabeculae of follicular epithelium in abundant hyalinized stroma (H and E, ×40), (c) Demonstrates remarkable inter and intratrabecular hyalinization (H and E, ×100), (d) Showing elongated tumor cell with round nuclei and moderate amphophilic cytoplasm. Focal granular calcification within the tumor noted (H and E, ×400)



**Figure 4:** IHC - (a and b) thyroid transcription factor shows nuclear positivity (a. ×40; b. ×400) with moderate intensity of staining, (c and d) Thyroglobulin exhibiting diffuse strong positivity



contain hyaline material, mimic amyloid that confuses it for medullary carcinoma thyroid. HTT was also designated as “paraganglioma-like adenoma of the thyroid” because of its histologic architectural resemblance to a neuroendocrine tumor. However, the HTT is derived from the follicular epithelium.<sup>[3,5]</sup> Resemblances of morphological features among these tumors make the diagnosis difficult.

The poorly differentiated tumor of thyroid is characterized by tumor cells having enlarged nuclei with prominent nucleoli, Presence of invasion, adhesion and metastases in the surrounding tissue and absence of follicle or colloid by light microscopy in the trabeculae.<sup>[6]</sup> In the present case, there was no evidence of adhesion or invasion. The nuclei were uniform and small, with no visible nucleoli. Occasional trabeculae showed follicles that were either empty or contained colloid.

Presence of RET/PTC translocations in HTT strengthen the fact that HTN is a variant of PTC. Some molecular features that distinguishing HTT and PTC include, First is mRNA which failed to reveal the characteristic up-regulation in HTT and is expressed in PTC and secondly mutations of the BRAF and N-RAS genes are found in PTC.<sup>[3]</sup>

The histological features in our case were strongly in favor of HTT, but Ki 67 (MIB-1) showed focal nuclear positivity rather than characteristic cytoplasmic/membranous expression as described by Hirokawa and Carney.<sup>[5,7]</sup>

A non histone protein Ki-67 antigen is expressed in G1, S, G2, and M phases, except G0. Ki 67 is available in clones like MIB-1, SP2, SP6 etc. by different manufactures. The MIB-1 monoclonal antibody has been frequently used to stain Ki-67 antigen.<sup>[5]</sup> Ki-67/MIB-1 has been identified as a useful marker in delineating between HTT and PTC. The positivity of Cell membrane or cytoplasm is in favor of HTT but its absence or non-reactivity does not exclude the diagnosis of HTT. This feature of MIB-1 is absent in PTC. Hirokawa and Carney stated that unique cytoplasmic MIB-1 (Ki-67) expression, in HTT is useful in making the distinction from PTC that is negative. However, negative MIB-1 stain has no diagnostic value.<sup>[7]</sup> Immunoreactivity for Ki67 varies according to the IHC methods and with different clones of Ki67. In our case we applied clone MIB-1 (Ki67) and clone SP6 immunohistochemical stain, both revealing focal nuclear positivity in <1% of cells.

Various pitfalls and troubles can cause false negative results with Ki 67; It may be due to type of method, under-fixation or over-fixation, degradation of antibody, dewaxing, antigen

retrieval temperature, few epitopes, tumor heterogeneity, technical error, and misinterpretation.<sup>[8]</sup>

Leonardo E *et al.*, in 2007 applied MIB-1 and different anti-Ki67 antibodies in HTT and other human tumors. They observed that the cell membrane reactivity in HTT by MIB-1 is obtained only if the reaction is performed at room temperature; because automated immunostainers which operate at 37 degrees do not produce any MIB-1 membrane localization.<sup>[9]</sup> Therefore MIB-1 focal nuclear positivity in our case could be due to variation in temperature during processing.

Nami T *et al.*,<sup>[11]</sup> used fully and semi automated strainers in 10 cases of HTT. They observed that MIB-1 using fully automated strainers may be negative, but in semi-automated strainers when antigen retrieval is carried out manually by using autoclave, pressure cooker, or microwave, membrane positivity will be raised. A similar phenomenon was reported by Park *et al.*,<sup>[10]</sup> In which fully automated (BOND-MAX), semi-automated (BOND-X) immune strainer (IHC) systems and a manual method of MIB-1 were done. BOND-X showed MIB-1 Monoclonal antibody revealing membranous positivity but BOND-MAX did not. The differences were in the IHC steps before the incubation with primary antibody. These findings indicate that antigen retrieval by fully automated stainers is insufficient for cell membranous staining of MIB-1 for HTTs.

This lack of true specificity suggests that alternative staining conditions be applied to detect the membranous immunoreactivity of Ki67 when the case suspected as HTT appears negative for Ki67 immunostaining.

Positivity of thyroglobulin, TTF and negativity for congo red exclude the possibility of paraganglioma and medullary thyroid carcinoma respectively.<sup>[11]</sup>

## CONCLUSION

In our case the common histological features are trabecular pattern, presence of nuclear grooving and hyalinized stroma. These features are also seen in other thyroid tumors. Exclusion of PDT, MC and paraganglioma can be achieved using histochemistry and immunohistochemistry in addition to morphology. IHC for Ki67 could produce unexpected results during the diagnosis of HTT. When staining for Ki67 is negative despite typical histological features of HTT, staining conditions should be altered to detect the characteristic membranous expression of Ki67.

## Financial support and sponsorship

Nil.

### Conflicts of interest

There are no conflicts of interest.

### REFERENCES

1. Takada N, Hirokawa M, Ohbayashi C, Nishikawa T, Itoh T, Imagawa N, *et al.* Re-evaluation of MIB-1 immunostaining for diagnosing hyalinizing trabecular tumour of the thyroid: Semi-automated techniques with manual antigen retrieval are more accurate than fully automated techniques. *Endocr J* 2018;65:239-44.
2. Ricardo V. Lloyd. *Borderline Thyroid Tumors in WHO Classification of Endocrine Organs*. 4<sup>th</sup> ed. 2017.
3. Jadhav DS, Dukare SR, Kale P. Hyalinizing trabecular tumor of the thyroid: A rare case report. *IJSR* 2015;4:817-20.
4. Andreas K, Efthimios P, Georgios G, Dimitrios L. Thyroid hyalinizing trabecular tumor: A case series. *Int J Med Pharm Case Reports* 2017;9:1-4.
5. Yufei L, Xin H, Yuchang H, Fei W, Tingting D, Weiwen H, *et al.* Hyalinizing trabecular tumor of the thyroid: A clinicopathological analysis of four cases and review of the literature. *Int J Clin Exp Pathol* 2017;10:7616-26.
6. Yuji O, Masashi K, Gang HL, MF, Mitsuyoshi H. A purely trabecular follicular adenoma of the thyroid gland, harboring extraordinarily long trabeculae. *Biomed Res* 2015;26:380-3.
7. Hirokawa M, Carney JA. Cell membrane and cytoplasmic staining for MIB-1 in hyalinizing trabecular adenoma of the thyroid gland. *Am J Surg Pathol* 2000;24:575-8.
8. Jones DJ, Kieliszk CR, Patel SS, Selinsky CR. Hyalinizing trabecular tumor of the thyroid gland and its significant diagnostic issue. *Thyroid Res* 2017;10:7.
9. Leonardo E, Volante M, Barbareschi M, Cavazza A, Dei Tos AP, Bussolati G, *et al.* Cell membrane reactivity of MIB-1 antibody to ki67 in human tumors: Fact or artifact? *Appl Immunohistochem Mol Morphol* 2007;15:220-3.
10. Park HS, Kim KM, Bae JS, Chung MJ, Lee H, Moon WS, *et al.* Diagnostic caveats of immunoreactivity for Ki67 and chromogranin A in hyalinizing trabecular tumour of the thyroid. *J Clin Pathol* 2014;67:835-9.
11. Liu H, Lin F. Application of immunohistochemistry in thyroid pathology. *Arch Pathol Lab Med* 2015;139:67-82.